

MORPHOLOGICAL CHANGES IN TASTE BUDS OF THE FUNGIFORM PAPILLAE AFTER A SINGLE DOSE OF X-RAY IRRADIATION IN RATS

ROSNAH BINTE ZAIN, BSc, MS* and C T HANKS. DDS. PhD**

*Department of Oral Pathology & Oral Medicine, Faculty of Dentistry, University of Malaya, Kuala Lumpur and **Department of Oral Pathology, School of Dentistry, University of Michigan, Ann Arbor, USA.

Summary

The qualitative and quantitative changes occurring in the taste buds of the fungiform papillae of male Sprague-Dawley rats (aged 51–125 days old) after x-ray irradiation were studied. A single dose of 2000 Roentgen (R) was delivered and observations were made at 0, 3, 7, 14, 21 and 30 days after x-ray irradiation. The changes in taste bud morphology were interpreted first as degenerative and then as regenerative at various stages of the study. The degenerative process appeared at about the third day and reached a peak at 7 days. Regeneration then began after a further week and the taste buds appeared mature at about 30 days. While the number of fungiform papillae remained constant throughout the study, there was a marked loss of taste buds on these papillae at 7 days. At 14 days, the number of taste buds increased from this low level, and by 30 days the number approached the control values. Initial taste bud loss could be attributed to a direct irradiation damage leading to taste bud cell desquamation combined with a concomitant mitotic inhibition of the stratum germinativum.

Keywords: Radiation injury, taste bud degeneration.

INTRODUCTION

In many clinical situations, decrease in taste sensation, altered taste sensation and complete loss of sensation have been noted to arise from a variety of causes. Among these are Sjogren's syndrome¹ and diseases involving the middle ear.¹ Similarly, therapeutic radiation may cause changes in taste sensitivities. Other complications that may occur after irradiation include mucositis, osteoradionecrosis, xerostomia and dental caries.³ These complications have been the subject of many post-irradiation studies.⁴⁻⁸

There have been few animal studies reported on the effects of irradiation on taste bud structure and function.⁹⁻¹¹ The data by Conger and Wells⁹ were mainly based on the taste buds of the circumvallate papillae. A loss of taste buds was shown to occur after x-ray irradiation.

In the mouse circumvallate papilla, more than one taste bud is observed in each papilla and these taste buds are situated on the dorsal surface and the lateral walls of the circumvallate papilla.¹² Since Conger and Wells' data⁹ was obtained from such papillae and the count was made on every tenth section, there may be

a certain degree of inaccuracy in their scoring. It is thus the purpose of this study to evaluate Conger and Wells' conclusions⁹ by accessing the qualitative and quantitative changes occurring in the taste buds of the fungiform papillae instead of the circumvallate papillae after x-ray irradiation. With fungiform papillae, the number of potential taste buds at the degenerated stage can be accurately ascertained, since Henderson and Smith¹³ have established that there is only one taste bud situated on the dorsal surface of each fungiform papilla in the rat. This is not possible with the circumvallate or foliate papilla.

MATERIALS AND METHODS

A total of 36 male Sprague-Dawley rats ranging from 51 to 125 days old were used. Even though ideally the age of the rats should be the same, Fish et al.² had shown that there is no significant difference in total number of taste buds within this age range. The rats were caged separately and fed on Purina rat chow and water *ad libitum*. These animals were divided into 6 groups. Groups one, two and three contained 5 animals each and were

sacrificed 3, 7 and 14 days respectively after x-ray irradiation. Groups four and five consisted of 6 animals each and they were sacrificed 21 and 30 days respectively after irradiation. The control group (untreated) consisted of 9 animals.

A single dose of 2000 Roentgen (R) was delivered to the experimental rats using a Westinghouse Coronade therapy machine operated at 250 Kv and 15 mA. An initial dose of 3000 R was used based on irradiation studies of salivary glands which was found to be non-lethal to the rats. Unfortunately, during our study a trial of such a dose caused death of most of the rats prior to the set time of observation. A further trial dose of 2500 R was also fatal to many rats and a final dose of 2000 R was found to be suitable. The x-ray beam was filtered through 0.5 mm copper and 1.0 mm aluminium. The target-skin distance was 50 cm. All animals in a group were irradiated at the same time. The x-ray irradiation beam was directed at the head and neck area with the trunks of the rat shielded by a rectangular lead plate measuring 35.6 cm x 38.1 cm x 0.30 cm (Fig. 1). These procedures were performed under anaesthesia achieved with an intraperitoneal injection of sodium pentobarbitol (35 mg per kg body weight). All animals were sacrificed under ether anaesthesia. The right tongue halves were fixed in neutral acetate-buffered 4% formalin. The tissue was then processed, embedded in paraffin and serially sectioned at 10 μ m. The sections were stained with Mayer's haematoxylin and eosin. The left tongue

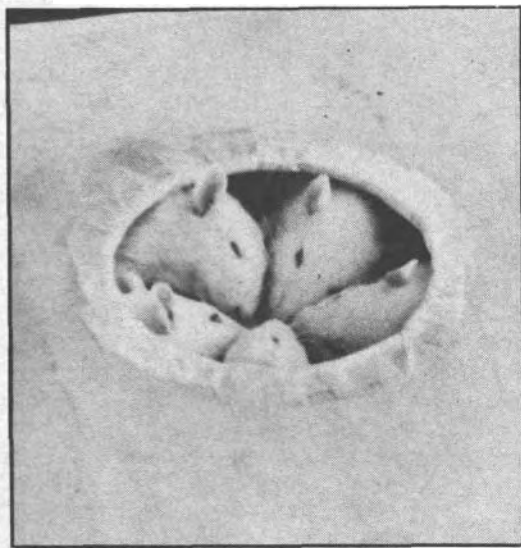


FIG. 1: Photograph showing the trunks of rats shielded by a lead plate.

halves were frozen, sectioned on a Lipstulz cryostat and then further processed for neural studies.

The first 100 sections corresponding to 1 mm of tissue from the tip of the tongue were discarded to avoid inaccurate counts as a result of the curving of the tongue tip due to fixation (the curving of the tip of the tongue would lead to oblique sections and difficulty in counting the taste buds). Each of the subsequent 400 sections were observed under light microscopy. Every fungiform papilla and taste bud was sequentially viewed and recorded throughout its thickness. In doing so, no fungiform papilla or taste bud was missed or counted twice. Qualitative and quantitative assessments were made of the fungiform papillae and taste buds.

Qualitative analysis

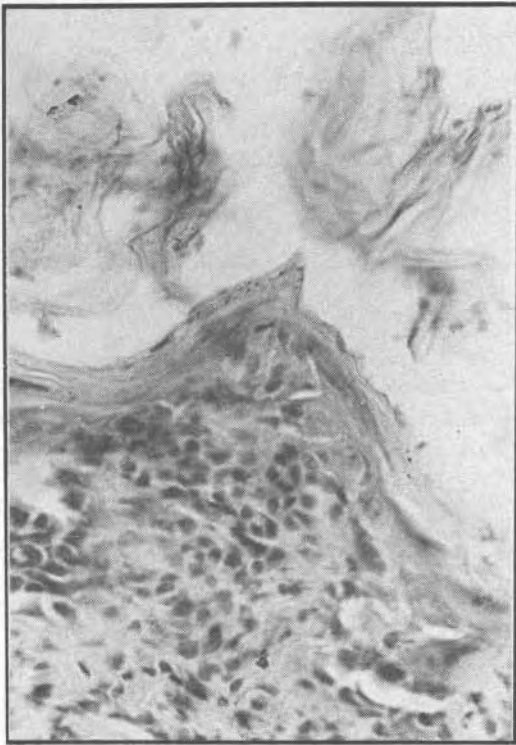
The taste buds were evaluated for changes in morphology interpreted as degeneration and regeneration. These morphological changes were divided into five stages as shown in Table 1 and Figs. 2a-2e. The distribution of the number of taste buds at the different stages of morphological change in each group was demonstrated by histograms. For each group a percentage was obtained where 100% represented the maximum number of taste buds that were present. Since every fungiform papilla in the rat usually has only one taste bud on the dorsal surface of the papilla,¹³ it can be assumed that the total number of fungiform papillae for each rat is the same as the total (maximum) number of taste buds. Only occasionally were two taste buds present in a papilla. The percentage of taste buds in a particular morphological group was calculated by dividing the observed number of taste buds in that group by the total number of fungiform papillae and multiplying by 100. A qualitative assessment was also made to estimate the average fungiform papillae and taste bud sizes. This was achieved by observing the number of 10 μ m sections in which each papilla and taste bud could be seen.

Quantitative analysis

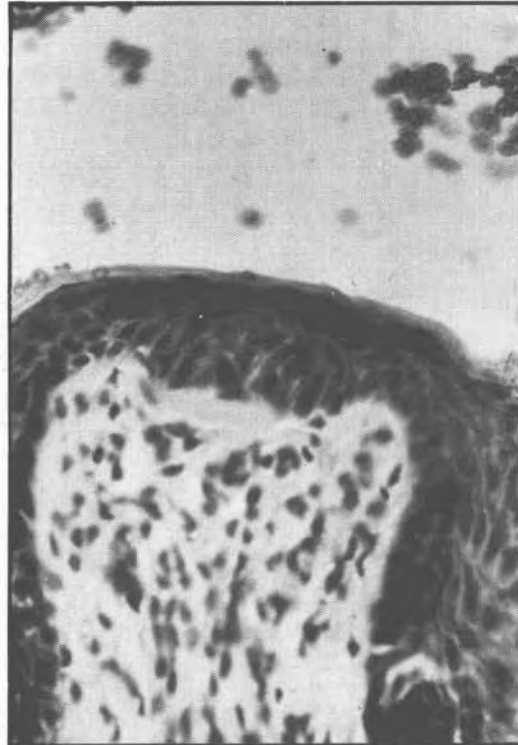
The population means of the number of taste buds and fungiform papillae of experimental and control rats were compared using the univariate one-way analysis of variance (ANOVA).¹⁴ After the analysis of variance had established that there was a difference between two groups, identification of specific difference between means was made using the Scheffe's multiple comparison procedure, where pairwise comparisons between groups were made.¹⁵

TABLE 1
MORPHOLOGICAL STAGES OF DEGENERATION AND
REGENERATION OF RAT FUNGIFORM PAPILLAE
TASTE BUDS FOLLOWING X-IRRADIATION

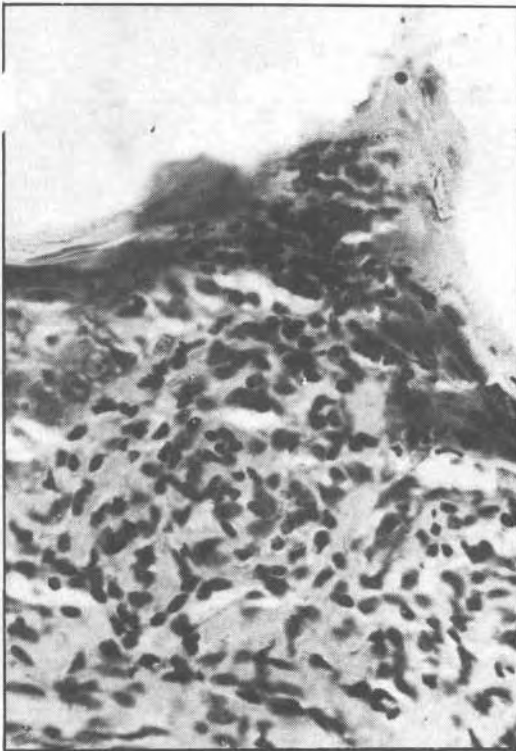
Stages		Morphological criteria	
a. Degenerating Taste bud	(-1)	1. Pore	- Absence of the apical pore.
		2. Architecture	- Bud cells do not fill the whole thickness of the epithelium. - Few bud cells are present.
		3. Nuclei	- The nuclei of the bud cells are oriented haphazardly.
b. No taste bud	0	-	No. taste buds are present in an existing papilla.
c. Early immature taste buds	1	1. Pore	- Absence of the apical pore.
		2. Architecture	- A collection of cells which break the regular epithelial-connective tissue contour of the papilla. - These cells are not well delineated from the surrounding epithelium.
		3. Nuclei	- Presence of dark staining nuclei.
d. Late immature taste buds	2	1. Pore	- Absence of the apical pore.
		2. Architecture	- A demarcation between bud cells and epithelium is evident. - The buds do not fill the entire thickness of the epithelium.
		3. Nuclei	- The nuclei are darkly stained and are not well-oriented.
e. Mature or normal taste buds	3	1. Pore	- Presence of the apical pore.
		2. Architecture	- The bud cells consist of clear cytoplasm. - The bud cells fill the thickness of the epithelium.
		3. Nuclei	- Dark and pale staining nuclei are present. - The bud cell nuclei are oriented at the taste bud.



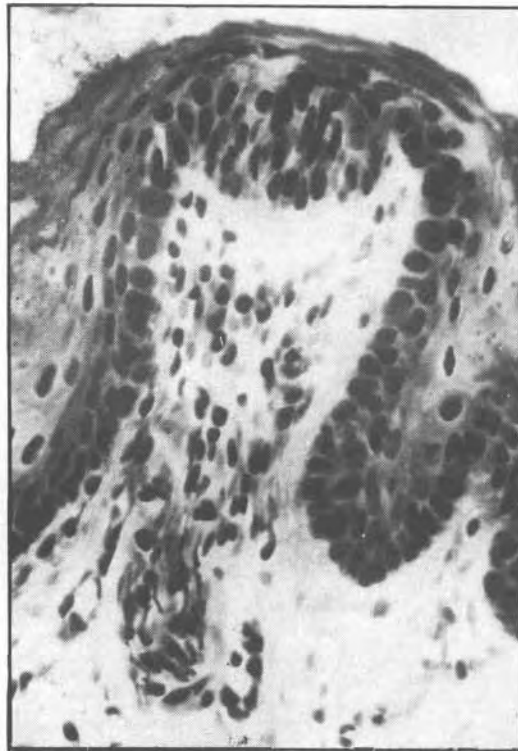
(a) Degenerating taste buds (Stage -1)



(c) Early immature taste buds (Stage 1)

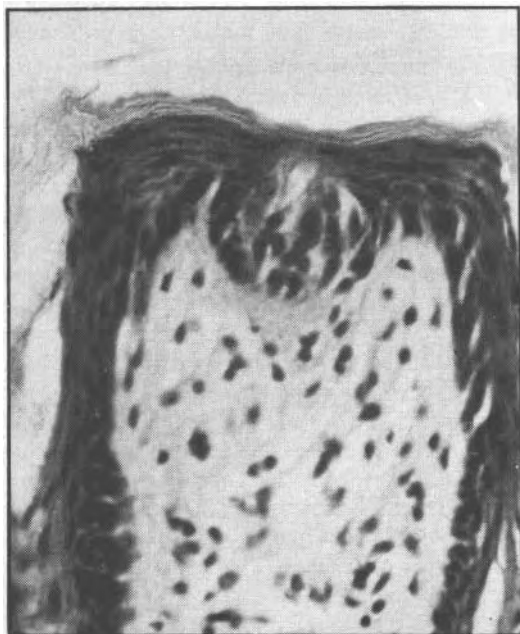


(b) Empty fungiform papillae (Stage 0)



(d) Late immature taste buds (Stage 2)

FIG. 2: Photomicrographs illustrating the morphological changes occurring in the taste buds of fungiform papillae after 2000 R of x-ray irradiation.



(e) Mature taste buds (Stage 3).

Dropouts and final material

Even though the initial number of rats was 36, the final number used for qualitative and quantitative assessment was 21. This was because 4 rats had died prior to sacrifice and 7 rat tongue specimens were discarded due to technical errors such as epithelial tears in more than two consecutive sections and failure of the staining technique. The former would most likely have led to a missed count since the smallest taste bud size is approximately 20 μm .¹⁶ Hence quantitative and qualitative evaluations were finally completed on 4 rats in group one, 2 rats in group two, 2 rats in group three, 2 rats in group four, 3 rats in group five and 8 rats in the control group. Since the average number of fungiform papillae per half rat tongue is 89.4 (178.8 per rat tongue),¹² the number of rats used for final evaluation could still yield a significant sample of taste buds and fungiform papillae.

RESULTS

Qualitative analysis

The distribution of the number of taste buds at the different stages of degeneration and regeneration in each group is presented in Fig. 3.

Control (non-irradiated)

A single taste bud was evident on the dorsal surface of each fungiform papilla with only about 2% of the papillae devoid of taste buds (Fig. 3). A large majority of taste buds were in the mature stage (Stage 3). Each of these mature taste buds contained a collection of pale elongated cells which spanned the thickness of the epithelium with pale and dark staining nuclei elongated parallel to the axis of the taste bud. An apical pore which opened onto the surface was easily identified (Fig. 2e - mature taste bud). The average papilla and taste bud sizes were 90 μm and 45 μm respectively.

Group One (3 days after x-ray irradiation)

Figure 3 shows that about 30% of the taste buds in Group 1 were degenerated, while the majority were mature (Fig. 2e). Some Stage 3 taste buds satisfied almost all the criteria of normality except for a slight disorientation of nuclei. The epithelium of the papillae which contained the taste buds was slightly distorted.

Group Two (7 days after x-ray irradiation)

The epithelium showed signs of atrophy with a few areas of ulceration and loss of cornified spines of the filiform papillae. Figure 3 shows that 15% of the taste buds were in Stage -1 (Fig. 2a) while 85% were in Stage 0 (empty fungiform papillae; Fig. 2b).

Group Three (14 days after x-ray irradiation)

Signs of regeneration were evident at this stage. The epithelium was restored to almost normal thickness. Filiform and fungiform papillae appeared morphologically normal except for slightly smaller sized fungiform papillae. Only 2% of the fungiform papillae were devoid of taste buds (Fig. 3) while the rest contained a single taste bud on the dorsal surface. Almost 10% of the taste buds were in Stage 1 (Figs. 2c and 3), and about 50% were in Stage 2 (Figs. 2d and 3). A few mature stage taste buds (Stage 3) were also present but without formation of apical pores. The average taste bud size appeared smaller than the control.


Group Four (21 days after x-ray irradiation)

The epithelium exhibited a thickness similar to the control. There was an increased number (55%) of mature taste buds (Fig. 3).

Group Five (30 days after x-ray irradiation)

Complete regeneration was evidenced by a normal epithelial thickness and normal fungiform and fungiform papillae structures. Approximately 80% of the taste buds observed were mature (Fig. 3). This was about 10% less than in the control group. The average taste bud size in this group appeared slightly smaller than the control group.

Quantitative analysis

The number of fungiform papilla and taste buds at 0, 3, 7, 14, 21 and 30 days after x-ray irradiation are graphically presented in Figs. 4a and b. Using the ANOVA, there was no significant difference between the means of the number of fungiform papillae ($P > 0.05$) at any one time period. However, there was a marked decrease in the number of taste buds at 7 days after treatment. The number  by 14 M and almost reached control levels by 30 days. The ANOVA showed the difference in numbers of taste buds observed to be highly significant ($P < 0.001$). Furthermore, the Scheffe's multiple comparison procedure identified that the significant difference lay between Group Two (7 days after x-ray irradiation) and the groups for other intervals.

DISCUSSION

Light microscopical signs of damage after a single dose of 2000 R were detected at 3 days after irradiation which was the first observation point in this study. By 7 days, almost all these taste buds had disappeared. This loss of taste buds in the rat fungiform papillae after irradiation correlates well with Conger and Wells' findings⁹ in the mouse circumvallate papillae. However the present investigation has the additional advantage of establishing the number of taste buds that should have been present. In the present study, no significant loss in the number of fungiform papillae was observed. However a slight reduction in the average size of the papilla as reported by Conger and Wells⁹ was similarly noted. During normal conditions, cells of the taste buds are renewed by mitosis within cells of the adjacent stratum germinativum.¹⁷ These cells enter the taste buds and differentiate into morphologically functional taste bud cells and are finally desquamated out of the taste bud. Beidler and Smallman,¹⁷

Conger and Wells,⁹ and Shaber¹¹ showed an average life span of 10–10.5 days for taste bud cells. Since 2 days were spent in mitosis outside the taste bud, the average time spent within the taste bud would be 8–8.5 days. As the maximum taste bud loss in this study is 7 days after x-ray irradiation, it could be hypothesized that there may be direct irradiation damage to the taste bud cell leading to a slightly faster rate of cell desquamation.

From 14 days to 30 days after irradiation, the taste buds showed progressive stages of regeneration. Such morphological progression has also been described for developing taste buds.^{18,19} Thus the regenerative process might be considered as analogous to taste bud development. The observation that at 14 days, more than 50% of the taste buds were immature (Stages 1 & 2) but 29% were mature (Stage 3), while at 21 days more than 50% were mature, seems to imply that a minimum of 7 days was required for the other 21% taste buds to mature. Furthermore Knowlton and Hoffman²⁰ have shown that x-ray irradiation interrupts mitotically cycling cells in mitosis in the stratum germinativum of the epiglottis. On the basis of this report and the present finding, the hypothesis that x-ray irradiation affects the mitotic activity of the stratum germinativum should be considered. In addition, the rest of the epithelium was markedly atrophic at 7 days after irradiation. The normal epithelial thickness was regained 14 days after irradiation, that is 7 days after the peak of epithelial damage had occurred. As atrophy of the tongue epithelium occurred simultaneously and within the same time interval as the complete loss of taste bud, the hypothesis that x-ray irradiation causes mitotic inhibition is further supported.

In summary, this study has shown that there is loss of taste buds but no change in the number of fungiform papillae 7 days after x-ray irradiation. The possible mechanism of taste bud loss could be a direct x-ray irradiation damage leading to taste bud cell desquamation combined with a concomitant mitotic inhibition of the stratum germinativum. Other possible mechanisms include an indirect damage to the nerve supplying the taste buds as suggested by Conger and Wells⁹ and xerostomia arising from radiation effects. The latter hypothesis is based on the report by Cano and Rodriguez²¹ that taste bud degeneration occurs in sialectomized rats. In addition they also observed normal nerve synapsing with the taste bud cell indicating that taste bud degeneration is not a consequence of neural deprivation. The presence of saliva has also

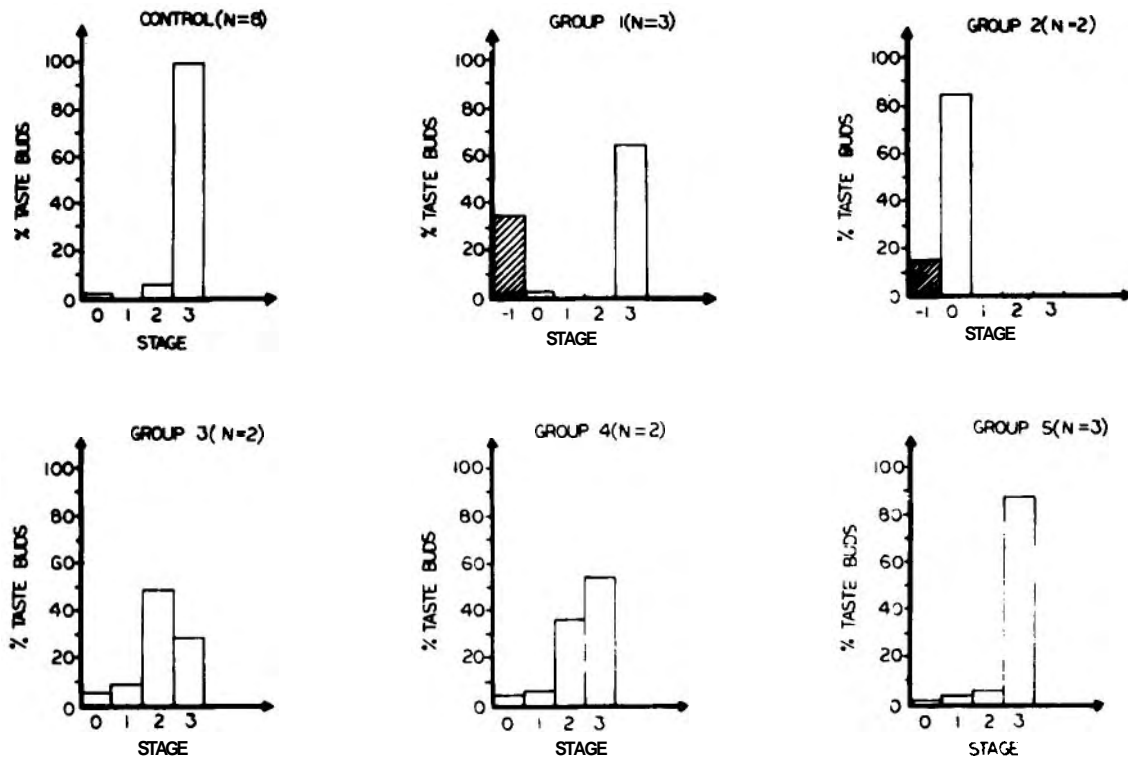


FIG. 3: The distribution of morphological changes in taste buds of rat fungiform papillae on sequential days after x-ray irradiation.

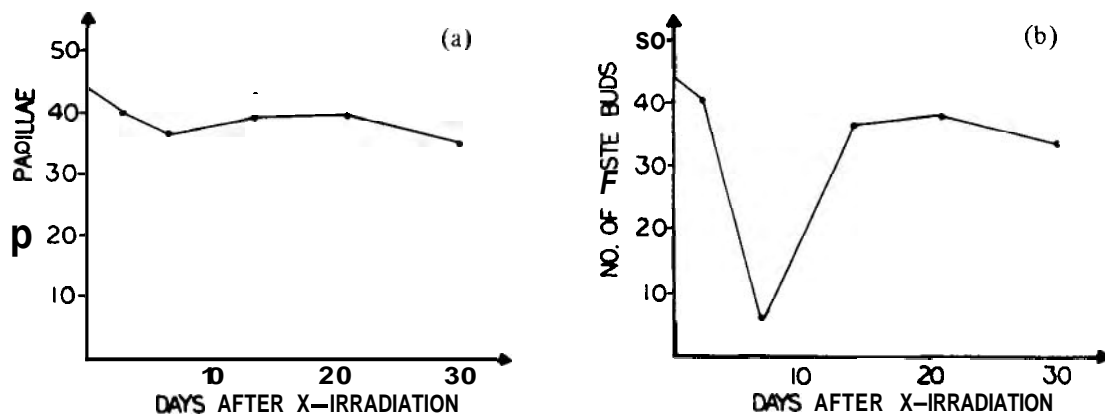


FIG. 4: (a) Number of fungiform papillae per 400 tissue sections versus days after x-ray irradiation. (b) Number of taste buds per 400 tissue sections versus days after x-ray irradiation.

been implicated in taste bud maintenance and function.^{2,2} All these mechanisms leading to taste bud loss after x-ray irradiation have not been fully substantiated and will require further research into these areas.

This study provides a possible pathogenetic basis for the clinical observation of loss or change in taste in patients following radiotherapy. Such an explanation would be reassuring to the patient since the taste bud loss can be replaced by regeneration of new taste buds.

ACKNOWLEDGEMENTS

We wish to thank Dr. C. Mistretta, Dr. R.M. Courtney and Mr. C. Cox for their constant advice throughout this research. This is part of a study that was carried out as a partial fulfilment of the requirement for the degree of Master of Science (Oral Pathology and Diagnosis) at The University of Michigan. This study was supported in part by the Department of Oral Pathology, University of Michigan and in part by the Kellogg Foundation. This paper has been presented at the Biennial Congress, International Association of Oral Pathologists in association with British Society of Oral Pathologists at Edinburgh in September 1986.

REFERENCES

- Henkin RI, Talal N, Larson AL et al. Abnormalities of taste and smell in Sjogren Syndrome. *Ann Intern Med* 1972; **76**(3): 375 - 83.
- Bull TR. Taste and the chorda tympani. *J Laryngol Otol* 1965; **79**: 479 - 93.
- Regezi JA, Courtney RM, Kerr DA. Dental managements of patients irradiated for oral cancer. *Cancer* 1976; **38**(2): 994 - 1000.
- Shafer WG. The effect of single and fractionated dose of selectively applied x-ray irradiation on the histologic structure of the major salivary glands of rat. *J Dent Res* 1953; **32**: 796 - 806.
- English JA. Enzymatic activity of radiated exteriorized salivary glands. *Am J Physiol* 1956; **186**: 245 - 2.
- Cherry CD, Glucksman MD. Injury and repair following irradiation of salivary glands in male rats. *Br J Radiol* 1949; **32**: 596 - 608.
- Leifer C. Morphologic and functional studies on rat parotid gland following sublethal x-irradiation. *Ph.D thesis*, State University of New York. 1971; 1 - 100.
- Rohrer WM, Kim Y, Fayos JV. The effect of cobalt-60 irradiation on monkey mandibles. *Oral Surg* 1979; **45**(5): 424 - 40.
- Conger AD, Wells MA. Radiation and aging effect on taste structure and function. *Rad Res* 1969; **37**: 31 - 49.
- Conger AD. Loss and recovery of taste acuity of in-patients irradiated to the oral cavity. *Rad Res* 1973; **53**: 338 - 47.
- Shaber GS. Alteration of taste thresholds in the rats following low doses x-irradiation. *Rad Res* 1971; **47**(3): 689 - 703.
- Fish HS, Malone PD, Richter CP. The anatomy of the tongue of the domestic Norway rat. 1. The skin of the tongue, the various papillae, their number and distribution. *Anat Rec* 1944; **89**: 429 - 40.
- Henderson PW, Smith JK. Developmental changes in rat fungiform papilla population. In: *Public Health Servicia*. NIH. Taste and development - the genesis of sweet preference. U.S. Dept. of Health, Education and Welfare. 1974: 70 - 84.
- Remington RD, Schork MA. Statistics with applications to biological and health sciences. Prentice-Hall, New Jersey. 1970: 282 - 306.
- Wonnacott TH, Wonnacott RJ. Introductory statistics. John Wiley and Sons, New York. 1977: 229 - 311.
- Guth L. The effects of glossopharyngeal nerve transection on the circumvallate papilla of the rat. *Anat Rec* 1957; **128**: 715 - 52.
- Beidler LM, Smallman RL. Renewal of cells within taste buds. *J Cell Biol* 1965; **27**: 263 - 72.
- Bradley RM, Stem IB. The development of human taste bud during foetal period. *J Anat* 1967; **101**: 743 - 52.
- Bradley RM, Mistretta CM. The morphological and functional development of fetal gustatory receptors. In: *Beidler LM, ed. Handbook of Sensory Physiology*. Volume 4; Part 2: Chemical senses. Springer-Verlag, Berlin, 1971: 239 - 53.
- Knowlton NP, Hoffman JG. The effects of x-rays on the mitotic activity of mouse epidermis. *Science* 1948; **107**: 625 - 6.
- Cano J, Rodriguez-Echiandia EL. Degenerative taste buds in sialectomized rats. *Acta Anat* 1980; **106**: 487 - 92.
- Catalonotto FA, Sweeny FA. The effects of surgical desalivation of the rat upon taste acuity. *Arch Oral Biol* 1972; **17**: 1455 - 65.