

ORIGINAL ARTICLE

Review of patients with *Strongyloides stercoralis* infestation in a tertiary teaching hospital, Kelantan

AZIRA NMS,^{*,**} ABDEL RAHMAN MZ^{*} and ZEEHAIDA M^{*}

^{*}Department of Medical Microbiology and Parasitology, Universiti Sains Malaysia, and ^{**}Cluster of Pathology and Laboratory Medicine, Faculty of Medicine, Universiti Teknologi Mara, Malaysia.

Abstract

Strongyloides stercoralis is an intestinal nematode infecting humans. The actual prevalence of infestation with this parasite in our setting is not well established. Thus, this study was conducted to determine the age, sex and co-morbid conditions among patients with *S. stercoralis* infestation as well as to study the common manifestations of strongyloidiasis in our patients. Records of patients with positive *S. stercoralis* larvae from January 2000 to December 2012 in Hospital Universiti Sains Malaysia, Kubang Kerian, Kelantan were reviewed. Ten patients were male and two were female. Their ages ranged from 19 to 78 years old. The majority (92%) of cases, presented with intestinal symptoms and 50% with moderate to severe anaemia. Thirty percent of cases had extraintestinal manifestations such as cough, sepsis and pleural effusion. Ninety-two percent of the patients had a comorbid illness. Most patients were immunocompromised, with underlying diabetes mellitus, retroviral disease, lymphoma and steroid therapy contributing to about 58% of cases. Only 58% were treated with anti-helminthic drugs. Strongyloidiasis is present in our local setting, though the prevalence could be underestimated.

Key words: *Strongyloides stercoralis*, diarrhoea, abdominal discomfort

INTRODUCTION

Strongyloides stercoralis is a widespread, soil-transmitted intestinal helminth, which infects millions of people worldwide.¹ It was first described in 1876 from stool specimens obtained from soldiers who had returned from Vietnam and were suffering from severe diarrhoea and other gastrointestinal symptoms.² Human infection occurs in endemic areas when the infective filariform larvae in contaminated soil actively penetrate the intact skin of the feet sole or hand palm; or the rhabditiform larva are ingested with contaminated food.³ Low socioeconomic backgrounds and habits that facilitate parasitic transmission are known to be the major risk factors for acquiring the primary infection.^{2,4}

The disease is generally asymptomatic in an immunocompetent person. It commonly manifests as intestinal symptoms, frequently diarrhoea, fever and abdominal pain. Some patients present with cough, dyspnoea or constipation.⁵ Complications include autoinfection which may

lead to hyperinfection syndrome (HS) which is a potentially serious life-threatening condition in immunocompromised and immunosuppressed patients.³ Generally, most of the patients have underlying co-morbidities for instance malnutrition, corticosteroid therapy, chronic obstructive airway disease, chronic liver disease or cirrhosis and peptic ulcer disease.⁵

The actual prevalence of infestation with this parasite in our setting is not well identified. The commonly associated risk factors for acquiring this parasitic infestation include traveling into an endemic area, working in the agriculture sector and gardening as well as visiting contaminated beaches.⁶

Current estimates indicate that at least 30-100 million people are infected with *S. stercoralis* in 70 countries, and the risk for developing advanced clinical complications is high in patients with certain underlying clinical conditions.^{2,7} However, the present global estimation for the prevalence of strongyloidiasis is not precise and accurate, since the infection is sometimes

misdiagnosed or difficult to detect because of the poor sensitivity of the usual applied diagnostic tests and the absence of reference standard (gold standard) that provides an absolute evidence for diagnosis.^{8,9} Therefore, *S. stercoralis* is considered to be the most neglected among soil-transmitted helminths infections.⁴

The disease has been studied among school-age children^{10,11}, travelers and immigrants,^{12,13} in tropical countries,¹⁴ subjects with low socioeconomic status and unhygienic habits,¹⁵⁻¹⁷ cancer patients,¹⁸ immunosuppressed patients,¹⁹ haematopoietic stem cell transplantation,¹⁹ and in HTLV-1-infected patients.²⁰ In addition, there are case reports of acute, relapsed and fatal strongyloidiasis.²¹⁻²⁴

The occurrence of strongyloidiasis varies widely among different countries, localities, and socioeconomic backgrounds.⁶ The disease is endemic in tropical, temperate and heavy rainfall areas.³

The prevalence of strongyloidiasis in Southeast Asia was determined as 11%.²⁵ In Malaysia, the prevalence of strongyloidiasis among cancer patients of all age groups who were treated with various chemotherapeutic regimes was reported as 5.7% (unpublished data). Rahmah *et al.*,¹⁶ had reported a prevalence of up to 1.2% among aborigine children. The epidemiology of *S. stercoralis* infection has been studied in much more detail in Thailand, especially among school children²⁶ and was noted as 1.8%, this being 6-30 times greater than previous reports reported in the same country.¹⁰

Infection with *S. stercoralis* is frequently imported to non-endemic areas by travelers and immigrants.²⁷ In Spain, the epidemiology of strongyloidiasis in the Mediterranean was described as 0.9% among patients who were elderly men and farmers who had walked barefooted.⁹ In the USA, 347 cases of strongyloidiasis-associated deaths occurred within a period of 15 years studied.²⁸ In the same country, it was found that half of cancer patients who had strongyloidiasis had solid organ malignancy and the remaining had haematologic malignancy.¹⁸ Meanwhile in Columbia, 3.6% of immunocompromised patients were found to be infected with *S. stercoralis*.²⁹

This study was conducted to determine the sex, age, geographical area and co-morbid conditions among patients with *S. stercoralis* infestation as well as to study the clinical manifestations of strongyloidiasis in our patients.

MATERIALS AND METHODS

Records of patients with positive *S. stercoralis* larvae from January 2000 to December 2012 in Hospital Universiti Sains Malaysia, Kubang Kerian, Kelantan were reviewed. A total of 15,155 of stool samples were received within this study period. Single direct stool microscopical examination was conducted. Wet mount preparation of stool concentrate with normal saline was done prior to microscopical examination of the larvae. The morphology of the larvae seen was described. Patient's demographic data such as age, sex, geographic area, co-morbid conditions and clinical manifestations were collected using a checklist. Data were analyzed and presented as descriptive statistics.

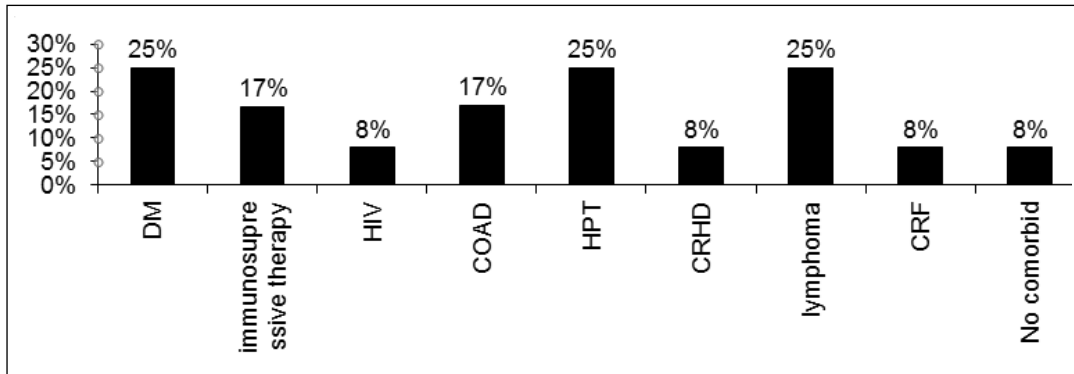
RESULTS

Only twelve cases were detected in 13-year period from year 2000 to 2012. The overall prevalence of *Strongyloides stercoralis* infection determined by the above method was 0.08% (12/15,155). Ten patients (83.3%) were male whereas two (16.7%) were female. Nine patients were aged more than 60 years old while three were less than 60. Most of the patients were from Bachok (4), followed by Terengganu (3), Kota Bharu (2), Pasir Putih (2) and Kuala Lumpur (1).

Ninety-two percent of the patients had a co-morbid illness. Patients were mainly immunocompromised patients, with underlying diabetes mellitus (DM), retroviral disease, lymphoma, chronic renal failure and steroid therapy contributing 58% of cases (7 out of 12) (Figure 1). Concurrent illness such as chronic obstructive airway disease (COAD), hypertension (HPT) and chronic rheumatic heart disease (CRHD) were also observed.

Our findings showed that most patients had intestinal manifestations which were mainly diarrhoea and abdominal discomfort (Table 1). Less than half of the patients had extra-intestinal manifestations. Twenty-five percent of patients most probably had developed secondary bacterial infections which lead to septicaemia.

Fifty-eight percent (7 out of 12) of patients were treated with albendazole. In terms of outcome, 11 patients survived while 1 died as a result of secondary septicaemia.



Note: DM- Diabetes mellitus; HIV: Human Immunodeficiency Virus; COAD; Chronic Obstructive airway Disease; HPT; Hypertensian; CRHD: Chronic Rheumatic Heart Disease, CRF; Chronic Renal Failure

FIG. 1: Percentage distribution of underlying co-morbidities in patients with *Strongyloides stercoralis* infestation.

DISCUSSION

Strongyloides stercoralis is an important intestinal helminthic infestation. It is endemic mainly in rural areas in Malaysia but the actual prevalence is not determined.

From our review of these strongyloidiasis patients, males are more prone to infestation compared to females. In our series, most of the male patients were farmers. Male gender has been attributed with higher prevalence of strongyloidiasis. This could be due to occupational exposure as most of the cases reviewed here are farmers. In addition, the cure rate of the infection in man is lower than that in female, and this condition is marked by the persistent elevation of serum IgG4.^{3,30} This finding was reported in previous studies.^{9,7}

Our centre is a referral centre for haematological malignancies such as lymphoma and leukaemia as well as solid organ cancers such as breast cancer. In this review, the majority of patients were immunocompromised. Although most patients had intestinal symptoms, some presented with extraintestinal symptoms such as pleural effusion. Immunocompromised and immunosuppressed conditions are identified as common risks associated with this infestation as well as contributing factors for developing hyperinfection syndrome (HS). Autoinfection can become amplified into a potentially fatal HS, characterized by increased numbers of infective filariform larvae in stool and sputum. Systemic manifestations attributable to increase parasite burden and migration, include gastrointestinal bleeding and respiratory distress.³

TABLE 1: Clinical manifestations in patients with *Strongyloides stercoralis* infestation

Symptoms/ signs	Number (%)
Intestinal symptoms	11 (92)
Diarrhea	9 (75)
Constipation	1 (8)
Abdominal discomfort	7 (58)
Anorexia	5 (42)
Extraintestinal symptoms	4 (33)
Cough	2 (17)
Pleural effusion	2 (17)
Sepsis	3 (25)
Others	
Moderate to severe anaemia	6 (50)
Fever	6 (50)
Weight loss	1 (8)

In disseminated strongyloidiasis, bacteraemia may develop as a result of translocation of enteric bacteria through the tract created by invading filariform larvae or bacteria itself can be carried on the larva. This stage is found not to be uncommon in the reviewed cases.³

There is no standard agreement on the screening of *S. stercoralis* in suspected patients. Routine diagnosis of strongyloidiasis is made by a combination of stool direct microscopy, concentration method, and culture method. Thus, there are many reasons that can explain a very low prevalence of strongyloidiasis among our patients in this study. The diagnosis of chronic strongyloidiasis from stool samples can be difficult and insufficiently sensitive to be used alone for screening because of intermittent larval output in stool^{31,32} which lead to a low yield of detection.³³ The low sensitivity of routine microscopical method may further contribute to the low prevalence of detected infection.

In addition, the possibility of other unreported cases may contribute to the overall low prevalence. Most patients especially immunocompetent patients are asymptomatic.³³ Thus, such patients were not presented to our setting.

On the other hand, the detection rate by direct stool microscopy is found to be increased during acute infection and hyperinfection as the result of increased larval output as reported previously.³⁴⁻³⁶ However, it is extremely uncommon to see acute infection or hyperinfection in routine clinical practice or in surveys, since most of the positive cases, if presented, are in the chronic phase of the infection. Therefore, direct microscopy alone is not useful in routine screening of strongyloidiasis unless it is combined with other detection methods or when the chronic disease turns into active hyperinfection.⁶

The detection of parasitic DNA in faecal samples using PCR-based methods proved to be a sensitive and specific method for the diagnosis of strongyloidiasis in individuals with or without clinical symptoms at all infection stages.^{37,38} Recent studies and case reports using *Strongyloides*-real-time PCR reported increased detection rates when compared with other stool-based procedures.³⁹ However, this method is not widely available and is expensive, limiting its use in developing countries.

Serological tests have shown a correlation between *S. stercoralis* infection and antibody level at all stages including acute, chronic, hyperinfection, after treatment (treatment follow-up), and cure.^{6,40} In addition, serodiagnosis using

ELISA appear to be useful in the diagnosis of strongyloides infection in immunosuppressed and immunocompetent patients.¹⁸ However, there are some limitations for ELISA that may affect results including: cross-reactions with other nematode infections; variable sensitivity and specificity; lack of a gold standard; and inability to differentiate between acute or chronic infections.^{2,41} In addition, the sensitivity of serology is good in individuals with chronic infection but is lower in those infected after travelling to endemic areas.^{38,42}

Albendazole is the preferred anti-helminthic in this setting in view of its single dosing which provides better compliance. Albendazole at 400 mg orally twice a day for 3 days has been shown to clear stools of *S. stercoralis* larvae in 38% to 45% and normalize serology in 75% of chronically infected individuals in whom larvae were not detectable.³

As most of the reviewed cases were immunocompromised patients, extra attention should be made in providing screening tests to those who are immunocompromised particularly those presenting with symptoms of chronic strongyloidiasis, steroid therapy, diabetic, HIV and patients with malignancy. This may help in reducing the risk of hyperinfection and disseminated strongyloidiasis. Screening of at risk individuals has also being suggested by Keiser *et al.*³

In conclusion, Strongyloidiasis is present in our local setting. However, as the current available method which is microscopy has low sensitivity, the actual prevalence of strongyloidiasis might be underestimated. Thus, other more sensitive methods such as molecular methods may help in determining the actual prevalence in this region. The infection should be looked for especially in immunosuppressed patients as its treatment would improve morbidity and mortality.

ACKNOWLEDGEMENTS

The authors would like to thank Mr. Nik Zairi Zakaria and Mr. Zulnuhisham Suhaimi from the Medical Microbiology and Parasitology Laboratory, School of Medical Sciences, Universiti Sains Malaysia for their technical assistance.

REFERENCES

1. Weinstein D, Lake-Bakaar G. *Strongyloides stercoralis* infection presenting with severe

- malabsorption and arthritis in an immune competent host. *Internet J Rheumatology*. 2006; 2(2). doi: 10.5880/13e9.
2. Siddiqui AA, Berk SL. Diagnosis of *Strongyloides stercoralis* infection. *Clin Infect Dis*. 2001; 33(7): 1040-7.
 3. Keiser PB, Nutman TB. *Strongyloides stercoralis* in the immunocompromised population. *Clin Microbiol Rev*. 2004; 17(1): 208-17.
 4. Olsen A, van Lieshout L, Marti H, *et al*. Strongyloidiasis - the most neglected of the neglected tropical diseases? *Trans R Soc Trop Med Hyg*. 2009; 103(10): 967-72.
 5. Tsai HC, Lee SS, Liu YC, *et al*. Clinical manifestations of strongyloidiasis in southern Taiwan. *J Microbiol Immunol Infect*. 2002; 35(1): 29-36.
 6. Marcos LA, Terashima A, Dupont HL, Gotuzzo E. Strongyloides hyperinfection syndrome: an emerging global infectious disease. *Trans R Soc Trop Med Hyg*. 2008; 102(4): 314-8.
 7. Yori PP, Kosek M, Gilman RH, *et al*. Seroepidemiology of strongyloidiasis in the Peruvian Amazon. *Am J Trop Med Hyg*. 2006; 74(1): 97-102.
 8. Lindo JF, Lee MG. *Strongyloides stercoralis* and *S. fulleborni*. In: Gillespie SH, Pearson RD, editors. *Principles and practice of clinical parasitology*. 1st ed. New York: John Wiley & Sons; 2001. p. 479-92.
 9. Sánchez PR, Guzman AP, Guillen SM, *et al*. Endemic strongyloidiasis on the Spanish Mediterranean coast. *QJM*. 2001; 94(7): 357-63.
 10. Anantaphruti MT, Nuamtanong S, Muennoo C, Sanguankiat S, Pampang S. *Strongyloides stercoralis* infection and chronological changes of other soil-transmitted helminthiasis in an endemic area of southern Thailand. *Southeast Asian J Trop Med Public Health*. 2000; 31(2): 378-82.
 11. Dada-Adegbola HO, Bakare RA. Strongyloidiasis in children five years and below. *West Afr J Med*. 2004; 23(3): 194-7.
 12. Loutfy MR, Wilson M, Keystone JS, Kain KC. Serology and eosinophil count in the diagnosis and management of strongyloidiasis in a non-endemic area. *Am J Trop Med Hyg*. 2002; 66(6): 749-52.
 13. Sudarshi S, Stümpfle R, Armstrong M, *et al*. Clinical presentation and diagnostic sensitivity of laboratory tests for *Strongyloides stercoralis* in travellers compared with immigrants in a non-endemic country. *Trop Med Int Health*. 2003; 8(8): 728-32.
 14. Vannachone B, Kobayashi J, Nambanya S, Manivong K, Inthakone S, Sato Y. An epidemiological survey on intestinal parasite infection in Khammouane Province, Lao PDR, with special reference to Strongyloides infection. *Southeast Asian J Trop Med Public Health*. 1998; 29(4): 717-22.
 15. Huminer D, Symon K, Groskopf I, *et al*. Seroepidemiologic study of toxocarasis and strongyloidiasis in institutionalized mentally retarded adults. *Am J Trop Med Hyg*. 1992; 46(3): 278-81.
 16. Rahmah N, Ariff RH, Abdullah B, Shariman MS, Nazli MZ, Rizal MZ. Parasitic infections among aborigine children at Post Brooke, Kelantan, Malaysia. *Med J Malaysia*. 1997; 52(4): 412-5.
 17. Machado ER, Teixeira EM, de Paula FM, Gonçalves-Pires MRF, Ueta MT, Costa-Cruz JM. Immunoparasitological diagnosis of *Strongyloides stercoralis* in garbage collectors in Uberlândia, MQ Brazil. *Parasitol Latinoam*. 2007; 62(3-4): 180-2.
 18. Safdar A, Malathum K, Rodriguez SJ, Husni R, Rolston KV. Strongyloidiasis in patients at a comprehensive cancer center in the United States. *Cancer*. 2004; 100(7): 1531-6.
 19. Schaffel R, Nucci M, Carvalho E, *et al*. The value of an immunoenzymatic test (enzyme-linked immunosorbent assay) for the diagnosis of strongyloidiasis in patients immunosuppressed by hematologic malignancies. *Am J Trop Med Hyg*. 2001; 65(4): 346-50.
 20. Hirata T, Uchima N, Kishimoto K, *et al*. Impairment of host immune response against *strongyloides stercoralis* by human T cell lymphotropic virus type 1 infection. *Am J Trop Med Hyg*. 2006; 74(2): 246-9.
 21. Abdelrahman MZ, Zeehaida M, Rahmah N, *et al*. Fatal septicemic shock associated with *Strongyloides stercoralis* infection in a patient with angioimmunoblastic T-cell lymphoma: a case report and literature review. *Parasitol Int*. 2012; 61(3): 508-11.
 22. Norsarwany M, Abdelrahman Z, Rahmah N, *et al*. Symptomatic chronic strongyloidiasis in children following treatment for solid organ malignancies: case reports and literature review. *Trop Biomed*. 2012; 29(3): 479-88.
 23. Prendki V, Fenaux P, Durand R, Thellier M, Bouchaud O. Strongyloidiasis in man 75 years after initial exposure. *Emerg Infect Dis*. 2011; 17(5): 931-2.
 24. Win TT, Sitiasma H, Zeehaida M. *Strongyloides stercoralis* induced bilateral blood stained pleural effusion in patient with recurrent Non-Hodgkin lymphoma. *Trop Biomed*. 2011; 28(1), 64-7.
 25. Genta RM. Global prevalence of strongyloidiasis: critical review with epidemiologic insights into the prevention of disseminated disease. *Rev Infect Dis*. 1989; 11(5): 755-67.
 26. Steinmann P, Zhou XN, Du ZW, *et al*. Occurrence of *Strongyloides stercoralis* in Yunnan Province, China, and comparison of diagnostic methods. *PLoS Negl Trop Dis*. 2007; 1(1): e75.
 27. van Doorn HR, Koelewijn R, Hofwegen H, *et al*. Use of enzyme-linked immunosorbent assay and dipstick assay for detection of *Strongyloides stercoralis* infection in humans. *J Clin Microbiol*. 2007; 45(2): 438-42.
 28. Croker C, Reporter R, Redelings M, Mascola L. Strongyloidiasis-related deaths in the United States, 1991-2006. *Am J Trop Med Hyg*. 2010; 83(2): 422-6.
 29. Botero JH, Castaño A, Montoya MN, Ocampo NE, Hurtado MI, Lopera MM. A preliminary study of the prevalence of intestinal parasites in immunocompromised patients with and without

- gastrointestinal manifestations. Rev Inst Med Trop Sao Paulo. 2003; 45(4): 197-200.
30. Walzer PD, Milder JE, Banwell JG, Kilgore G, Klein M, Parker R. Epidemiologic features of *Strongyloides stercoralis* infection in an endemic area of the United States. Am J Trop Med Hyg. 1982; 31(2): 313-9.
 31. Marty FM. Strongyloides hyperinfection syndrome and transplantation: a preventable, frequently fatal infection. Transpl Infect Dis. 2009; 11(2): 97-9.
 32. Wirk B, Wingard JR. *Strongyloides stercoralis* hyperinfection in hematopoietic stem cell transplantation. Transpl Infect Dis. 2009; 11(2): 143-8.
 33. Mora CS, Segami MI, Hidalgo JA. *Strongyloides stercoralis* hyperinfection in systemic lupus erythematosus and the antiphospholipid syndrome. Semin Arthritis Rheum. 2006; 36(3): 135-43.
 34. Kia EB, Rahimi HR, Mirhendi H, *et al.* A case of fatal strongyloidiasis in a patient with chronic lymphocytic leukemia and molecular characterization of the isolate. Korean J Parasitol. 2008; 46(4): 261-3.
 35. Azira NM, Zeehaida M. *Strongyloides stercoralis* hyperinfection in a diabetic patient: case report. Trop Biomed. 2010; 27(1): 115-9.
 36. Stewart DM, Ramanathan R, Mahanty S, Fedorko DP, Janik JE, Morris JC. Disseminated *Strongyloides stercoralis* infection in HTLV-1-associated adult T-cell leukemia/lymphoma. Acta Haematol. 2011; 126(2): 63-7.
 37. ten Hove RJ, van Esbroeck M, Vervoort T, van den Ende J, van Lieshout L, Verweij JJ. Molecular diagnostics of intestinal parasites in returning travellers. Eur J Clin Microbiol Infect Dis. 2009; 28(9): 1045-53.
 38. Verweij JJ, Canales M, Polman K, *et al.* Molecular diagnosis of *Strongyloides stercoralis* in faecal samples using real-time PCR. Trans R Soc Trop Med Hyg. 2009; 103(4): 342-6.
 39. Basuni M, Muhi J, Othman N, *et al.* A pentaplex real-time polymerase chain reaction assay for detection of four species of soil-transmitted helminths. Am J Trop Med Hyg. 2011; 84(2): 338-43.
 40. Rodrigues RM, de Oliveira MC, Sopelete MC, *et al.* IgG1, IgG4, and IgE antibody responses in human strongyloidiasis by ELISA using *Strongyloides ratti* saline extract as heterologous antigen. Parasitol Res. 2007; 101(5): 1209-14.
 41. Boulware DR, Stauffer WM, Hendel-Paterson BR, *et al.* Maltreatment of Strongyloides infection: case series and worldwide physicians-in-training survey. Am J Med. 2007; 120(6): 545. e1-8.
 42. Marcos LA, Terashima A, Canales M, Gotuzzo E. Update on strongyloidiasis in the immunocompromised host. Curr Infect Dis Rep. 2011; 13(1): 35-46.