

## Significance of Bcl-2 and Bax proteins in cervical carcinogenesis: an immunohistochemical study in squamous cell carcinoma and squamous intraepithelial lesions

Phaik-Leng CHEAH, MD, FRCPath and Lai-Meng LOOI, MD, FRCPath

Department of Pathology, Faculty of Medicine, University of Malaya, Kuala Lumpur, Malaysia

### Abstract

Sixteen low grade (LSIL), 22 high grade (HSIL) squamous intraepithelial lesions, 28 invasive (13 stage I and 15 stage II-IV) squamous cell carcinoma (SCC) and 15 benign cervixes were immunohistochemically studied for involvement of Bcl-2 and Bax proteins in cervical carcinogenesis. 4- $\mu$ m sections of the cases were immunostained for Bcl-2 (Clone 124: Dako) and Bax (Dako) and staining intensity was rated as 1 (light), 2 (moderate) and 3 (strong) and percentage cellular staining as 0 (negative), 1 (1-25%), 2 (26-50%), 3 (51-75%) and 4 (>75%) with score derived by multiplying staining intensity and percentage positivity. The cut-off value, indicating upregulated expression, was computed as >2 for Bcl-2 and >8 for Bax. Bcl-2 was upregulated ( $p < 0.05$ ) in HSIL and Bax in SCC when compared with benign cervical squamous epithelium. Bcl-2 expression was confined to the lower third of the epithelium in the benign cervixes and LSIL. In HSIL, expression reached the middle and upper thirds. 4 (30.8%) HSIL with upregulated Bcl-2 demonstrated intensification of staining around the basement membrane. SCCs showed “diffuse” (evenly distributed) or “basal” (intensified staining around the periphery of the invading tumour nests) expression of Bcl-2. Of the 5 SCCs with upregulated Bcl-2, 1 of 2 (50%) stage I and 3 (100%) stage II-IV tumours exhibited the “basal” pattern. Benign cervical squamous epithelium, LSIL, HSIL and SCC showed a generally diffuse Bax expression. Thus, Bcl-2 and Bax appeared to be upregulated at different stages of cervical carcinogenesis, Bcl-2 in HSIL and Bax after invasion. Intensification of staining of Bcl-2 at the basement membrane in some HSIL and SCC is interesting and may augur for increased aggressiveness.

**Key words:** cervical carcinoma, Bcl-2, Bax, immunohistochemistry

### INTRODUCTION

Since the recognition of apoptosis or “programmed cell death” in the early 1970s,<sup>1,2</sup> there has been much progress in the understanding of its role in development and homeostasis of an organism, with the Bcl-2 gene identified as one of the most prominent regulators of apoptosis. Located on chromosome 18 the prototype Bcl-2 gene encodes a 25 kilodalton protein that suppresses apoptosis and is expressed on cell membranes<sup>3-7</sup>. In 1993 Oltvai *et al.* identified Bax, a 21 kilodalton protein that shares extensive homology with Bcl-2 and is capable of heterodimerisation with and countering the death repressor activity of Bcl-2.<sup>8</sup> Since then, at least 16 family members, sharing a minimum of one of 4 conserved Bcl-2 homology (BH) domains, have been recognised in

humans with some demonstrating anti-apoptotic and others pro-apoptotic properties.<sup>9-11</sup>

After the first description of Bcl-2-induced failed programmed cell death leading to B-cell follicular lymphoma,<sup>12-14</sup> Bcl-2 and Bax have been extensively studied and alterations in protein expressions have been noted in other tumours including carcinoma of the prostate, breast and stomach etc.<sup>15-17</sup> Studies of these proteins in cervical carcinoma have been generally scarce. Cervical squamous intraepithelial lesions and invasive cervical squamous cell carcinoma were immunostained for Bcl-2 and Bax proteins and compared with benign cervical squamous epithelium to assess the involvement of Bcl-2 and Bax proteins in cervical carcinogenesis from the intraepithelial neoplastic stage to overtly invasive carcinoma.

## MATERIALS AND METHODS

Sixteen low-grade (LSIL), 22 high-grade squamous intraepithelial lesions (HSIL) and 28 cervical invasive squamous cell carcinoma (SCC) diagnosed histologically for the first time at the Department of Pathology, University of Malaya Medical Centre, Kuala Lumpur were entered into the study. 13 SCC were in stage I, 12 stage II, 2 stage III and 1 stage IV. Cervices from 15 hysterectomies with or without salpingo-oophorectomies performed for non-malignant diseases in the female genital tract, except the cervix, served as benign controls. All cases, both benign and neoplastic had been histologically reviewed previously and diagnoses re-confirmed.

Two consecutive 4  $\mu$ m tissue sections were cut from the selected paraffin blocks of the 10% formalin-fixed cases and benign controls on to aminopropyltriethoxysilane (TESPA) coated slides. The sections were subjected to 2 cycles of microwave antigen retrieval (Energy Beam Sciences, Inc., 600 watts, 100% power at 90°C for 2.5 min each cycle) before immunohistochemical staining. Immunohistochemical staining using the respective antibodies: monoclonal anti-human Bcl-2 protein (Clone 124; Dako, dilution 1:50) and polyclonal anti-human Bax protein (Dako, dilution 1:200) was carried out with the peroxidase labelled streptavidin biotin kit (Dako). The final results were visualised via diaminobenzidine tetrahydrochloride. A reactive lymph node served as positive control for both Bcl-2 and Bax. Negative controls were derived by substituting phosphate buffered saline for the primary antibody. Positive and negative controls were included in each batch of immunostaining. Furthermore, inflammatory cells noted to be present in all the neoplastic and benign cervixes served as internal controls for both Bcl-2 and Bax.

Bcl-2 and Bax immunopositivity ("cytoplasmic" for both proteins) were semi-quantitated by visual impression. Staining intensity was graded as 1 (light), 2 (moderate) and 3 (strong). Percentage of cells expressing the proteins was rated as 0 (negative), 1 (1-25%), 2 (26-50%), 3 (51-75%) and 4 (>75%). In the squamous intraepithelial lesions, the proportion of cells staining positively was compared against the total number of cells in the squamous epithelium visibly identifiable as neoplastic. For the benign cervixes, percentage positivity was based on immunoreactive compared with the total number of squamous cells at the squamo-

columnar junction. The "score" was derived for Bcl-2 and Bax by multiplying the staining intensity and percentage positivity for each protein. Cut-off values indicating upregulated expressions of Bcl-2 and Bax were formulated based on the highest score of each protein achieved by "majority" (at least 90%) of the benign cervixes. In practice, not more than 1 of the 15 benign cervixes should show a score above the cut-off value. Statistical analysis was carried out using Fisher's exact test and interpreted at 5% level of significance.

## RESULTS

### *Bcl-2 and Bax expressions in benign cervical squamous epithelium*

Bcl-2 was expressed in 8 benign squamous epithelium. Bcl-2 scores of the 15 benign cervixes ranged from 0-4 with 7 achieving score 0, 6 score 1, 1 score 2 and 1 score 4. The cut-off value indicating upregulated expression was set as >2. Immunoreactive cells were confined to the lower third of the squamous epithelium. All the benign squamous epithelium expressed Bax. 3 cases scored 3, 1 scored 4, 5 scored 6 and 6 scored 8. The cut-off value for Bax was set as score >8. Immunopositive cells were evenly distributed throughout the benign squamous epithelium.

### *Bcl-2 expression in SCC, LSIL and HSIL*

Bcl-2 expression was noted in 10 (35.7%) SCC, 10 (62.5%) LSIL and 17 (77.3%) HSIL. In SCC, Bcl-2 score >2 was noted in 5 (17.9%) but this upregulation was not significant ( $p>0.05$ ) when compared with benign squamous epithelium (6.7%). 2 of 13 (15.4%) stage I and 3 of 15 (20.0%) higher (II-IV) stage tumours showed upregulated Bcl-2 ( $p>0.05$ ). 2 distinct patterns of immunoreactivity were noted viz (1) "basal" with intensification of immunoreactivity at the periphery of the invading tumour nests (Figure 1) and (2) "diffuse" with an even distribution of the immunopositive cells (Figure 2). Of the 5 SCC with Bcl-2 score >2, 1 (50.0%) stage I and all 3 (100.0%) higher stage tumours demonstrated the basal pattern. No LSIL attained Bcl-2 score >2 although a significantly increased number of HSIL (59.1%) ( $p<0.05$ ) showed upregulated Bcl-2 (score >2). As in benign cervical squamous epithelium, Bcl-2 immunoreactive cells were evenly distributed and limited to the lower third of the epithelium in LSIL. In comparison, immunopositive cells reached beyond the lower third i.e. up to the middle and upper thirds in all

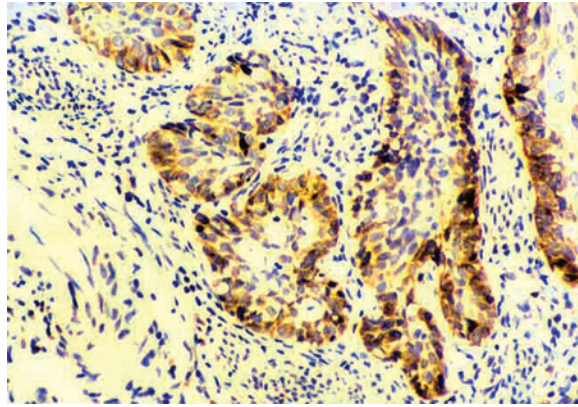


FIG. 1: A case of invasive cervical squamous carcinoma showing the “basal” pattern of Bcl-2 expression with intensification of immunoreactivity at the periphery of tumour clumps.

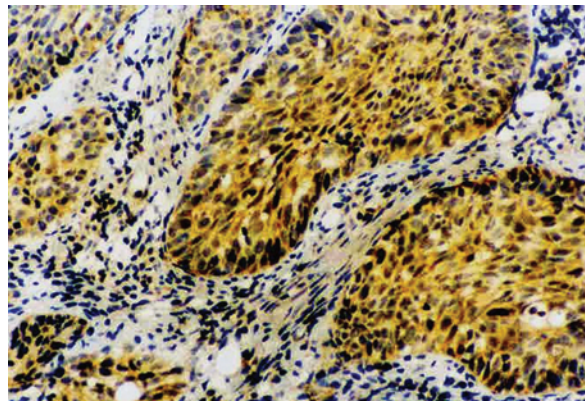


FIG.2: More even distribution of Bcl-2 immunopositivity throughout the tumour clumps in a case of invasive cervical squamous carcinoma demonstrating the “diffuse” staining pattern.

17 HSIL which expressed Bcl-2. Furthermore, there was intensification of staining in the basal layer in 4 HSIL (all with Bcl-2 scores >2).

*Bax expression in SCC, LSIL and HSIL*

Bax was expressed in 26 (92.9%) SCC, 12 (75.0%) LSIL and 22 (100.0%) HSIL. SCC demonstrated significantly upregulated Bax expression (score >8) when compared with benign cervixes ( $p < 0.05$ ). Bax upregulation showed no significant difference ( $p > 0.05$ ) between stage I (53.8%) and higher stage tumours (20.0%). LSIL and HSIL did not show significant Bax upregulation. Expression of Bax was generally diffuse and immunoreactive cells evenly distributed in LSIL, HSIL and SCC.

Table I shows Bcl-2 and Bax expressions in benign cervixes, LSIL, HSIL and SCC by immunopositivity and scores.

**DISCUSSION**

Bcl-2 was significantly upregulated in HSIL and Bax in SCC when compared with benign cervical squamous epithelium, implying a role of these proteins in the development of cervical squamous neoplasia. Increase of Bcl-2 expression in HSIL has also been noted by other workers.<sup>18-22</sup> However, it remains unclear whether this upregulation provides HSIL cells a survival advantage because of the anti-apoptotic properties of Bcl-2. The reason for proapoptotic Bax upregulation in SCC is also uncertain but may be associated with increased cell turnover. At this juncture, it is imperative to reiterate that Bcl-2 and Bax are part of a superfamily, where members are capable of homo and heterodimerisation with and augmenting or nullifying each other. Hence interpretation of Bcl-2 and Bax expressions must always take this into account. It is undetermined whether

**TABLE 1: Bcl-2 and Bax immunopositivity and upregulated expressions (Bcl-2 score >2; Bax score >8) in benign cervixes, low-grade squamous and high-grade-squamous intraepithelial lesions and invasive squamous carcinoma of the uterine cervix**

	Bcl-2		Bax	
	Positive (%)	Score >2 (%)	Positive (%)	Score >8 (%)
Benign cervixes (n=15)	8 (53.3)	1 (6.7)	15 (100.0)	0
LSIL (n=16)	10 (62.5)	0 (0)	12 (75.0)	0
HSIL (n=22)	17 (77.3)	13 (59.1)	22 (100.0)	0
SCC (n=28)	10 (35.7)	5 (17.9)	26 (92.9)	10 (35.7)

Notes: LSIL = low-grade squamous intraepithelial lesion; HSIL = high-grade squamous intraepithelial lesion; SCC = invasive cervical squamous carcinoma

Bcl-2 is actually downregulated in SCC or has heterodimerised with upregulated Bax or another family member resulting in decreased “free” Bcl-2 but it is noteworthy that in this study 9 (39.1%) of the 23 SCC with Bcl-2 score <2 showed upregulated Bax in comparison with only one (20%) of the 5 cases of SCC with upregulated Bcl-2. Studies in other adenoma/dysplasia-carcinoma sequences have also shown Bcl-2 downregulation after malignant change.<sup>23</sup> Further studies with increased number of cases and inclusion of other proapoptotic members of the family should help clarify the situation.

The occurrence of two different patterns of Bcl-2 immunoreactivity in SCC in this study has also been previously reported.<sup>24,26</sup> Interestingly of the 5 SCC with upregulated Bcl-2, 1 of 2 (50.0%) stage I tumours compared with all 3 (100.0%) higher stage tumours demonstrated the basal pattern of staining. In LSIL, the immunoreactive cells were confined, as in benign cervixes, to the lower third of the epithelium but reached beyond the lower third in all HSIL, suggesting increasing deviation from the normal with disease progression. In addition, 4 (30.8%) HSIL with Bcl-2 upregulation exhibited some intensification of staining in the basal layer, this phenomenon being also described by Tjalma *et al.* in cervical squamous carcinoma-in-situ.<sup>20</sup> Although the limited number of cases defeats proper analysis it highlights a possibility that antiapoptotic protein may be concentrated at the invading front of SCC and HSIL during certain periods. This may facilitate acquisition of distinct properties for more aggressive behaviour. Nevertheless, no significant correlation was noted between Bcl-2 and Bax upregulation (Bcl-2 score >2, Bax score >8) with tumour stage. Hence it may be

also useful, particularly in the study of Bcl-2, to consider distribution of the immunopositive cells besides staining intensity and proportion of immunoreactive cells.

As a postscript, it is pertinent to mention that all SCC, HSIL, LSIL and benign controls demonstrated the presence of inflammatory cells, which in fact constituted the internal positive controls. Whether injuries to the cervixes which led to the infiltration of inflammatory cells may have influenced the balance of Bcl-2 and Bax is a matter for speculation. Furthermore, scores were determined by multiplying a 3-point scale for staining intensity by a 4-point scale for percentage immunopositivity. This method inherently imparts a certain bias on to proportion of cells stained was an attempt to lessen the uncertainties encountered with intensity of immunohistochemical staining in the computation.

#### ACKNOWLEDGEMENT

This study was funded by the Malaysian Ministry of Science, Technology and Innovation IRPA research grants 06-02-03-0736 and 06-02-03-0575

#### REFERENCES

1. Warner TF. Apoptosis. *Lancet* 1972;2:1252.
2. Kerr JF, Wyllie AH, Currie AR. Apoptosis: a basic biological phenomenon with wide-ranging implications in tissue kinetics. *Br J Cancer* 1972;26:239-57.
3. Monaghan P, Robertson D, Amos TAS, Dyer MJS, Mason DY, Greaves MF. Ultrastructural localization of bcl-2 protein. *J Histochem Cytochem* 1992;40:1819-25.
4. Krajewski S, Tanaka S, Takayama S, Schibler MJ,

- Fenton W, Reed JC. Investigation of the subcellular distribution of the bcl-2 oncoprotein: residence in the nuclear envelope, endoplasmic reticulum and outer mitochondrial membranes. *Cancer Res* 1993;53:4701-14.
5. De Jong D, Prins FA, Mason DY, Reed JC, Van Ommen GB, Kluin PM. Subcellular localization of the bcl-2 protein in malignant and normal lymphoid cells. *Cancer Res* 1994;54:259-60.
  6. Chen-Levy Z, Cleary ML. Membrane topology of the bcl-2 proto-oncogene protein demonstrated in vitro. *J Biol Chem* 1990;265:4929-33.
  7. Akao Y, Otsuki Y, Kataoka S, Ito Y, Tsujimoto Y. Multiple subcellular localization of bcl-2: detection in nuclear outer membrane, endoplasmic reticulum membrane and mitochondrial membrane. *Cancer Res* 1994;54:2468-71.
  8. Oltvai ZN, Milliman CL, Korsmeyer SJ. Bcl-2 heterodimerizes in vivo with a conserved homolog, Bax, that accelerates programmed cell death. *Cell* 1993;74:609-19.
  9. Chao DT, Korsmeyer SJ. BCL-2 family: regulators of cell death. *Annu Rev Immunol* 1998;16:395-419.
  10. Reed JC. Bcl-2 family proteins. *Oncogene* 1998;17:3225-36.
  11. Zamzami N, Brenner C, Marzo I, Susin S, Kroemer G. Subcellular and submitochondrial mode of action of Bcl-2-like oncoproteins. *Oncogene* 1998;16:2265-82.
  12. Tsujimoto Y, Finger LR, Yunis J, Nowell PC, Croce CM. Cloning of the chromosome breakpoint of neoplastic B cells with the t(14;18) chromosome translocation. *Science* 1984;226:1097-99.
  13. Tsujimoto Y, Cossman J, Jaffe E, Croce CM. Involvement of the bcl-2 gene in human follicular lymphoma. *Science* 1985;228:1440-3.
  14. Tsujimoto Y, Croce CM. Analysis of the structure, transcripts, and protein products of bcl-2, the gene involved in human follicular lymphoma. *Proc Natl Acad Sci USA* 1986;83:5214-8.
  15. Krajewska M, Fenoglio-Preiser CM, Krajewski S, et al. Immunohistochemical analysis of Bcl-2 family proteins in adenocarcinomas of the stomach. *Am J Pathol* 1996;149:1449-57.
  16. Krajewska M, Krajewski S, Epstein JI, et al. Immunohistochemical analysis of bcl-2, bax, bcl-x and mcl-1 expression in prostate cancers. *Am J Pathol* 1996;148:1567-76.
  17. Veronese S, Mauri FA, Caffo O, et al. Bax immunohistochemical expression in breast carcinoma: a study with long term follow-up. *Int J Cancer* 1998;79:13-8.
  18. Saegusa M, Takano Y, Hashimura M, Shoji Y, Okayasu I. The possible role of bcl-2 expression in the progression of tumors of the uterine cervix. *Cancer* 1995;76:2297-303.
  19. Dimitrakakis C, Kymionis G, Diakomanolis E, et al. The possible role of p53 and bcl-2 expression in cervical carcinomas and their premalignant lesions. *Gynecol Oncol* 2000;77:129-36.
  20. Tjalma W, De Cuyper E, Weyler J, et al. Expression of bcl-2 in invasive and in situ carcinoma of the uterine cervix. *Am J Obstet Gynecol* 1998;178:113-7.
  21. ter Harmsel B, Kuijpers J, Smedts F, Jeunink M, Trimboos B, Ramaekers F. Progressing imbalance between proliferation and apoptosis with increasing severity of cervical intraepithelial neoplasia. *Int J Gynecol Pathol* 1997;16:205-11.
  22. Dellas A, Schultheiss E, Holzgreve W, Oberholzer M, Torhorst J, Gudat F. Investigation of the Bcl-2 and C-myc expression in relationship to the Ki-67 labelling index in cervical intraepithelial neoplasia. *Int J Gynecol Pathol* 1997;16:212-8.
  23. Nakamura T, Nomura S, Sakai T, Nariya S. Expression of bcl-2 oncoprotein in gastrointestinal and uterine carcinomas and their premalignant lesions. *Hum Pathol* 1997;28:309-15.
  24. Tjalma W, Weyler J, Goovaerts G, De Pooter C, Van Marck E, van Dam P. Prognostic value of bcl-2 expression in patients with operable carcinoma of the uterine cervix. *J Clin Pathol* 1997;50:33-6.
  25. ter Harmsel B, Smedts F, Kuipers J, Jeunink M, Trimboos B, Ramaekers F. Bcl-2 immunoreactivity increases with severity of CIN: a study of normal cervical epithelia, CIN, and cervical carcinoma. *J Pathol* 1996;179:26-30.
  26. Ohno T, Nakano T, Niibe Y, Tsujii H, Oka K. Bax protein expression correlates with radiation-induced apoptosis in radiation therapy for cervical carcinoma. *Cancer* 1998;83:103-10.