

Kikuchi's lymphadenitis (necrotizing lymphadenitis) and systemic lupus erythematosus: a case report

Shyamala H FERNANDEZ, MBBS, MPath

Department of Pathology, Hospital Sultanah Aminah Johor Baru

Abstract

A 26-year-old Indian lady was admitted for lower abdominal pain, diarrhoea, vomiting, fever and cough. The initial diagnosis was that of peritonitis secondary to ruptured or perforated viscus with lobar pneumonia. On laparotomy, she was found to have necrotizing or Kikuchi's lymphadenitis of the abdominal lymph nodes. The initial two antinuclear antibody (ANA) results came back negative. She was diagnosed to have systemic lupus erythematosus (SLE) when the third sample for ANA came back positive and the double-stranded DNA (dsDNA) antibody test was homogeneously positive. This case illustrates a need to be aware that necrotizing lymphadenitis can precede the onset of systemic lupus erythematosus.

Key words: Necrotizing lymphadenitis, Kikuchi's disease, anti-nuclear antibody, dsDNA antibody, systemic lupus erythematosus

INTRODUCTION

In 1972, Kikuchi¹ and Fujimoto *et al*² independently described the histological and clinical features of a lymph node disorder which they termed as "lymphadenitis showing focal reticulum cell hyperplasia with nuclear debris and phagocytosis" and "cervical subacute necrotizing lymphadenitis" respectively. Additional reports subsequently appeared in the Japanese literature employing a variety of terms such as "histiocytic necrotizing lymphadenitis,"³ "phagocytic necrotizing lymphadenitis"⁴ and "subacute necrotizing lymphadenitis."⁵ The subsequent 4 years from 1972 saw a series of reports appearing in the literature, indicating the recognition of this disorder in India,⁶ Greece? Hong Kong,⁸ Australia: the United Kingdom,¹⁰ Italy" and the United States of America^{12,13} The characteristic clinical, morphological and immunological features of Kikuchi's disease were described in detail, thus establishing this disease as a distinctive clinicopathological entity.¹⁴

The disease occurs more frequently in young women and manifestations include enlargement of the cervical lymph nodes, sometimes with fever, and often associated with non-specific clinical signs.¹⁵ Laboratory tests are often normal. The diagnosis is established on the basis of histological examination of excised involved lymph nodes. It generally needs no treatment because it runs a spontaneously benign course

with complete resolution of the symptoms within 6 months. Secondary systemic lupus erythematosus may develop. For this reason, regular follow-up of patients is recommended. The aetiopathogenesis of this disease is still unknown, perhaps due to an immunological phenomenon. It could be a hyperimmune reaction induced by various antigenic agents (such as infectious or neoplastic) or an autoimmune process.¹⁶

In the literature, only 22 cases of Kikuchi's lymphadenitis have been reported in the past to be associated with systemic lupus erythematosus (SLE), whether as a precedent, concurrent or postdated event.¹⁷⁻²⁶ This case is reported to increase awareness of this rare occurrence.

CASE REPORT

A 26-year-old Indian lady was referred to Hospital Sultanah Aminah Johor Baru from Hospital Kota Tinggi with the complaint of lower abdominal pain for the past one week. The pain was sudden in onset, colicky in nature and not related to either meals or posture. There was associated abdominal distension for two days prior to admission as well as high grade fever with chills and rigors. She also had diarrhoea, vomiting and productive cough. On examination, she was found to be ill-looking, pale and tachycardic. There was guarding and rebound tenderness at the left iliac fossa. Bowel sounds

Address for correspondence and reprint requests: Dr. Shyamala H Fernander, Department of Pathology, Hospital Sultanah Aminah, Johor Baru, Malaysia.

were absent. Per rectal examination revealed tenderness at the left rectal wall. There was decreased air entry of the right lung but no crepitations or rhonchi were elicited. Chest X-ray showed diffuse patchy opacities. Abdominal X-ray revealed dilated large bowels while the ultrasonogram showed pelvic collections probably secondary to a perforated viscus possibly the appendix.

A provisional diagnosis of peritonitis secondary to ruptured appendix or perforated viscus or pelvic inflammatory disease, with right lobar pneumonia was made. She was then referred to the medical team who started her on intravenous antibiotics (Cefobid, Flagyl and Erythromycin). CT scan of the thorax, abdomen and pelvis revealed bilateral pleural effusion, para-aortic and paracaval lymphadenopathy, fatty liver, left ovarian cyst and a thickened rectal wall. A diagnosis of lymphoma was then also entertained. She had a gynaecological referral for per vaginal discharge in order to rule out pelvic inflammatory disease as well as carcinoma of the ovary with secondaries. Both ovaries were found to be normal clinically. A bone marrow aspiration was carried out, which showed no significant abnormality.

She continued to have intermittent high fever and as the cause of her fever was not ascertained, she was then investigated for pyrexia of unknown origin. ANA carried out twice was negative. She was referred to the surgical unit for a lymph node biopsy. A staging laparotomy and splenectomy was also carried out. The working

diagnosis was lymphoma. Wedge biopsies of the right and left lobes of the liver were taken. Other specimens sent for histopathological examination were paracolic lymph nodes, para-aortic lymph nodes, paracaval nodes, splenic hilar nodes, hepatoduodenal nodes and the spleen.

Pathology

Histological examination of the paracolic (middle and right colic) lymph nodes revealed extensive paracortical necrotizing areas with abundant karyorrhectic debris, fibrin deposition and scattered large mononuclear cells (Fig.1). Scanty neutrophils and plasma cells were seen. No granuloma formation or malignancy were detected. Dystrophic calcification was also evident (Fig. 2). The para-aortic nodes showed reactive lymph nodal tissue with a focus of karyorrhectic debris and scanty polymorphonuclear leucocytes as well as plasma cells. Sections from the para-aortic nodes, paracaval nodes, splenic hilar nodes and hepatoduodenal nodes showed reactive changes with no evidence of inflammation or malignancy. The spleen weighed 105 gms. It was congested and revealed no evidence of granulomatous inflammation or malignancy.

Clinical course

The patient was diagnosed to have Kikuchi's or necrotizing lymphadenitis involving the middle colic, right colic and para-aortic lymph nodes.

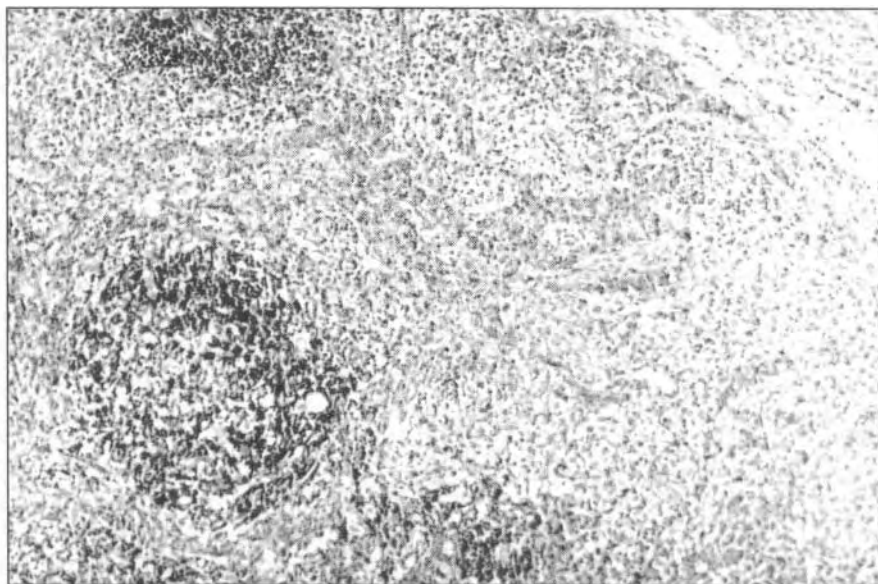


FIG. 1: Lymph node showing necrotizing lymphadenitis characterized by an abundance of nuclear debris. H&E X 100.

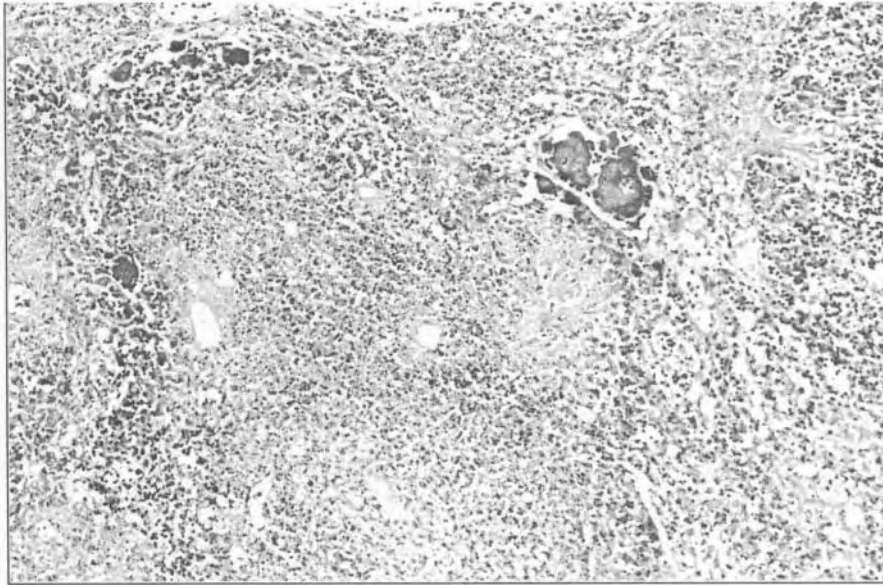


FIG. 2: Foci of dystrophic calcification in an area of necrotizing lymphadenitis. H&E X 100.

She was started on oral prednisolone, 40 mg daily. On the fourth post-operative day, she developed fits of about two minutes' duration. Biochemical investigations revealed a low serum sodium level (hyponatremia). She also developed bilateral lower leg pitting oedema and continued to have intermittent fever. Almost 6 weeks after admission, a third serum sample revealed a positive ANA result. Her dsDNA antibody test was also homogenously positive. As the patient was noticed to have abnormal behaviour, CT scan of the brain which was carried out but it revealed essentially normal findings except for mild cerebral atrophy. The patient was finally diagnosed as systemic lupus erythematosus with cerebral lupus, nephrotic syndrome, anaemia and septicaemia. The source of the infection was not ascertained.

DISCUSSION

Chen *et al*¹⁷ reported four cases of SLE with Kikuchi's disease in Taiwan. All the patients were females with a mean age of 30 years (age range from 21 to 35 years). The mean history of SLE was 4 years (with a range of 10 days to 8 years). Three patients developed Kikuchi's disease accompanied with flare-up of lupus activity while one had Kikuchi's disease simultaneously with the onset of SLE. One patient had ribosomal-P antibodies, one had ribonuclear protein (RNP) antibodies and none had antibodies to Ro(SSA) or La(SSB). The cause of association of Kikuchi's disease with

SLE remains unclear. From the cases studied, the high frequency of flare-up of lupus disease activity accompanied with the onset of Kikuchi's disease and the simultaneous occurrence of these two diseases indicate that they are not independent events. Therefore, it was speculated that Kikuchi's disease may be one of the manifestations of SLE.

Tumiati *et al*¹⁹ described a case of Kikuchi's disease in association with SLE where SLE preceded Kikuchi's disease. It was uncertain whether Kikuchi's disease was an independent event or directly connected with SLE. In a later article, Tumiati *et al*²⁵ reported two cases of SLE with the findings of Kikuchi's disease on lymph node biopsy. The authors suggested the possibility of Kikuchi's disease and SLE sharing a common aetiology because of the common infectious and/or immunological aetiologies described in both the disorders. This was reiterated by Eisner *et al*²⁶ who concluded that SLE can be complicated by necrotizing lymphadenitis and that there was a relationship between the two disorders as they both shared some common clinical and pathological features. Meyer *et al*²⁰ reported three cases of SLE associated with Kikuchi's disease and immunologically proven human parvovirus B19 infection. Simultaneous occurrence of SLE and Kikuchi's disease was characteristic of all three cases. A positive IgM-specific anti-human parvovirus B19 antibody test in the three cases suggested that B19 induced a necrotizing

histiocytic lymphadenitis and possibly a clinical SLE flare.

Martinez *et al*²¹ described two cases of Kikuchi's disease associated with SLE. The diagnosis of Kikuchi's disease in one case was made several years before the diagnosis of SLE and the other was simultaneous. The lymph node biopsies showed necrosis with proliferation of histiocytes and immunoblasts, paucity of neutrophils and absence of haematoxin bodies. It was concluded that patients with Kikuchi's disease should be assessed for SLE and have long term follow-up checking for the development of SLE. Kikuchi's disease should be considered in SLE flare-up accompanied by lymphadenopathy.

Hoffman *et al*²⁴ reported a case of a 37-year-old woman with Kikuchi-Fujimoto disease and SLE. Serological testing for human herpesvirus-6 (HHV-6) antibodies revealed an active infection. An excised cervical lymph node contained HHV-6 genome demonstrated by using *in situ* hybridization. Active HHV-6 infection should be considered in Kikuchi's disease.

Imamura *et al*²⁷ proposed that Kikuchi's disease may reflect a self-limited SLE-like autoimmune condition induced by virus-infected transformed lymphocytes. It is of further interest that both Kikuchi's disease and SLE have a remarkable predilection for young women.

In the case report described, the patient presented with lymphadenopathy involving an unusual site i.e. abdominal lymph nodes. Kikuchi's disease preceded her flare-up of SLE by a few weeks. Prior to her presentation of fever and abdominal pain, the patient was relatively well. Diagnostic markers for SLE, antinuclear antibodies (twice negative) and double stranded DNA antibodies, were only positive after the diagnosis of Kikuchi's disease was made. As noted by Martinez *et al*,²¹ the diagnosis of Kikuchi's disease can precede, postdate or coincide with the diagnosis of SLE. It seems that these two diseases appear to go hand-in-hand and therefore, there must be a common aetiological factor. Further investigations and **follow-up** may cast more light on this matter. The foci of dystrophic calcification encountered in the lesions probably have no significance other than a consequence of necrosis.

Is Kikuchi's disease in SLE an independent or dependent event or are the two disorders a common entity? This still appears to be highly speculative even though some studies have shown the coexistence of both conditions

suggesting the possibility that they share a common **aetiology**.^{17,25,26} Nevertheless, in most instances, Kikuchi's disease occurs as a separate entity from SLE.

This case serves to remind that necrotizing lymphadenitis indistinguishable from classical Kikuchi's disease may precede the diagnosis of SLE. It may be expedient to consider such a possibility in young women in whom such necrotizing lesions are encountered in an unusual site, such as intra-abdominal lymph nodes.

REFERENCES

1. Kikuchi M. Lymphadenitis showing focal reticulum cell hyperplasia with nuclear debris and phagocytosis. *Nippon Ketsueki Gakkai Zasshi* 1972; 35: 379-80.
2. Fujimoto Y, Kozima Y, Yamaguchi K. Cervical **subacute** necrotizing lymphadenitis. A new clinicopathological entity. *Naika* 1972; 20: 920-7.
3. Kikuchi M, Iwakaki H, Mitsui T. Clinicopathological study on histiocytic necrotizing lymphadenitis (so-called necrotizing lymphadenitis). *J Jpn Soc Res* 1980 (suppl); 20: 11-2.
4. Kikuchi M, Uryu Y. Phagocytic necrotizing lymphadenitis. *Med Bull Fukuoka Univ* 1976; 3: 321-2.
5. Fujimori T, Shioda K, Sussman EB et al. **Subacute** necrotizing lymphadenitis. A clinicopathologic study. *Acta Pathol Jpn* 1981; 31: 791-7.
6. Suseelan AV, Augusty TS, Harilal KR. Necrotizing lymphadenitis: An analysis of 17 cases. *Indian J Pathol Microbiol* 1984; 27: 331-4.
7. Papadimitriou CS, Papacharalampous NX. Histiocytic necrotizing lymphadenitis without **granulocytic** infiltration. *Arch Pathol Lab Med* 1985; 109: 107-8.
8. Chan JKC, Saw D. Histiocytic necrotizing lymphadenitis (Kikuchi's disease): A clinicopathologic study of nine cases. *Pathology* 1986; 18: 22-8.
9. Ma DDF, Hollis RR, Delbridge L. Histiocytic necrotizing lymphadenitis (Kikuchi's disease). *Aus N Z J Med* 1986; 16: 711-3.
10. Ali MH, Horton LWL. Necrotizing lymphadenitis without granulocytic infiltration (Kikuchi's disease). *J Clin Pathol* 1985; 38: 1252-7.
11. Carbone A, Manconi R, Volpe R, et al. Enzyme and immunohistochemical study of a case of histiocytic necrotizing lymphadenitis. *Virchows Arch (A)* 1986; 408: 637-47.
12. Evans CS, Goldman RL, Klein HZ, et al. Kikuchi's necrotizing lymphadenitis. *West J Med* 1985; 143: 346-8.
13. Unger PD, Rappaport KM, Strauchen JA. Necrotizing lymphadenitis (Kikuchi's disease): Report of four cases of an unusual pseudolymphomatous lesion and immunologic marker studies. *Arch Pathol Lab Med* 1987; 111: 1031-4.

14. Dorfman RF and Berry GJ. Kikuchi's histiocytic necrotizing lymphadenitis: an analysis of 108 cases with **emphasis** on differential diagnosis. *Semin Diag Pathol* 1988; **5(4)**: 329-45.
15. **Ayache** D, Rocher P, Buzyn-Veil A, Roulleau P. Kikuchi's disease. Apropos of a case. Review of the literature. *AM Otolaryngol Chir Cervicofac* 1993; **110(8)**: 478-81.
16. Bequignon A, Moreau S, Goulet de Ruyg M, Bourdon N, Babin E, Valdazo A. A case of Kikuchi disease. Review of the literature. *AM Otolaryngol Chir Cervicofac* 1996; **113(4)**: 233-6.
17. Chen YH, Lan JL. Kikuchi disease in systemic lupus erythematosus: clinical features and literature review. *Chung Hua Min Kuo Wei Sheng Wu Chi Mien I Hsueh Tsa Chii* 1998; **31(3)**: 187-92.
18. el-Ramahi KM, Karrar A, Ali MA. Kikuchi disease and its association with systemic lupus erythematosus. *Lupus* 1994; **3(5)**: 409-11.
19. Tumiati B, Bellelli A, Portioli I, Prandi S. Kikuchi's disease in systemic lupus erythematosus: an independent or dependent event? *Clin Rheumatol* 1991; **10(1)**: 90-3.
20. Meyer O, Kahn MF, **Grossin** M, Ribard P, Belmatoug N, Morinet F et al. **Parvovirus** B19 infection can induce histiocytic necrotizing lymphadenitis (Kikuchi's disease) associated with systemic lupus erythematosus. *Lupus* 1991; **1(1)**: 37-41.
21. Martinez-Vazquez C, Hughes G, Bordon J, Alonso-Alonso J, Anibarro-Garcia A, Redondo-Martinez E et al. Histiocytic necrotizing lymphadenitis, Kikuchi-Fujimoto's disease, associated with systemic lupus erythematosus. *QJM* 1997; **90(8)**: 531-3.
22. Biasi D, **Caramaschi** P, **Carletto** A, Residori C, **Randon** M, Friso S et al. Three clinical reports of Kikuchi's lymphadenitis combined with systemic lupus erythematosus. *Clin Rheumatol* 1996; **15(1)**: 81-3.
23. Meyer O, Ribard P, Belmatoug N, Kahn MF, **Grossin** M, **Fournet** JC et al. 3 cases of Kikuchi's lymphadenitis in systemic lupus erythematosus. Role of the **parvovirus** B19. *Ann Med Inteme (Paris)* 1991; **142(4)**: 259-64.
24. **Hoffman** A, Kim E, Kuerten A, Sander C, **Krueger** GR, Ablashi DV. Active human herpesvirus-6 (HHV-6) infection associated with Kikuchi-Fujimoto disease and systemic lupus erythematosus (SLE). *In Vivo* 1991; **5(3)**: 265-9.
25. Tumiati B, **Casoli** P, **Gasparini** E, Carretti C, **Portioli** I. Necrotizing lymphadenitis (Kikuchi's disease) and systemic lupus erythematosus: a single entity? *Ann Ita Med Int* 1993; **8(1)**: 25-8.
26. Eisner MD, Amory J, Mullaney B, Tiemey L Jr, Browner WS. Necrotizing lymphadenitis associated with systemic lupus erythematosus. *Semin Arthritis Rheum* 1996; **26(1)**: 477-82.
27. Imamura M, Ueno H, Matsumura A, et al. An ultrastructural study of **subacute** necrotizing lymphadenitis. *Am J Pathol* 1982; **107**: 292-9.