

## Immunotactoid glomerulopathy – an unusual deposition disease: report of the first Malaysian case

Phaik-Leng CHEAH *MPath, FRCPPath*, Lai-Meng LOOI *FRCPPath, FRCPA*, \*Rozina Ghazalli *MBBS, MRCP* and \*\*Chin-Teong CHUA *MBBS, FRCP*

*Departments of Pathology and \*\*Medicine, Faculty of Medicine, University of Malaya, Kuala Lumpur and \*Penang General Hospital.*

### Abstract

A 31-year-old Malay female presented with nephrotic syndrome without renal impairment. Renal biopsy features were in keeping with immunotactoid glomerulopathy (ITG). Non-Congophilic deposits were seen causing thickening of the glomerular capillary basement membrane with segmental accentuation, and widening of the mesangium. Immunofluorescence examination showed moderate amounts of IgG and C3 in the glomerular capillary walls with some in the mesangium. Ultrastructurally, 20-nm thick fibrils with microtubular organisation were present predominantly in the subendothelial region with similar fibrils in the mesangium. Although immunotactoid glomerulopathy and fibrillary glomerulonephritis (FG) have been recognised as entities with extracellular fibrillary material in the kidney, to date much remains to be clarified regarding these 2 conditions. While the renal biopsy findings in this patient are consistent with ITG, her clinical presentation is unlike that of usual ITG in that she is of a much younger age and has no associated haemopoietic disorder. Response to initial treatment of 8 weeks of prednisolone therapy was poor.

**Key words:** Kidney, immunotactoid glomerulopathy, fibrillary glomerulonephritis, nephrotic syndrome

### INTRODUCTION

Several types of extracellular fibrillary material have been recognised in the kidneys. Although amyloidosis constitutes the large majority of such deposition disorders, two more recently described entities include fibrillary glomerulonephritis and immunotactoid glomerulopathy. Both show non-Congophilic, ultrastructurally identifiable fibrils or microtubules. Fibrillary glomerulonephritis (FG) was first described in 1977 by Rosenmann and Eliakim<sup>1</sup> while immunotactoid glomerulopathy (ITG) was described in 1980 by Schwartz and Lewis.<sup>2</sup> Although there remains considerable controversy as to whether fibrillary glomerulonephritis and immunotactoid glomerulopathy constitute separate clinicopathological entities,<sup>3-5</sup> morphological distinction of FG from ITG is generally possible based on fibril diameter and pattern of arrangement. Larger than amyloid fibrils (8-15nm), the average 20 nm diameter (range 15-30nm) of FG fibrils are smaller compared with that of ITG (average diameter 40nm; range 20-50nm). FG fibrils resemble amyloid fibrils in its

random arrangement while ITG microtubular fibrils show at least some focal organisation. We describe a 31-year-old Malay female with organised non-amyloid, fibrillary glomerular deposits, the first documented Malaysian case of an immunotactoid glomerulopathy.

### CASE REPORT

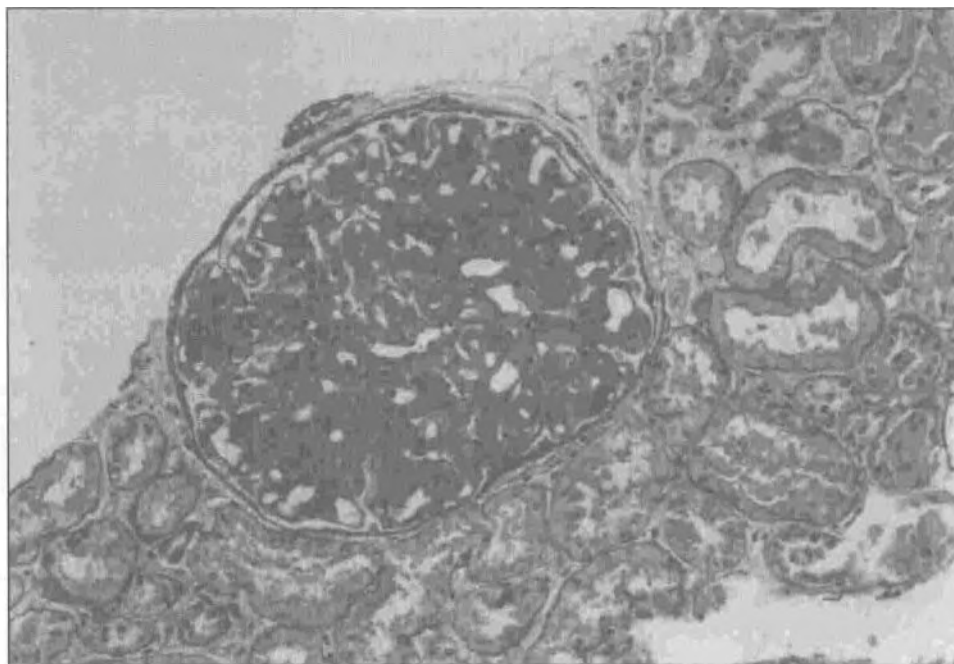
A 31-year-old Malay woman first presented to the Penang General Hospital with complaints of intermittent facial puffiness and ankle oedema of a year's duration which had worsened. On examination she had generalised oedema. Blood pressure was 105/70 mm Hg. Otherwise she had no other significant physical signs. 24-hour urine protein was 6.68 g. Total serum protein was lowered (46 g/l) especially in the albumin fraction (25 g/l). Both fasting serum cholesterol (11.1 mmol/l) and triglycerides (2.4 mmol/l) were elevated. Blood urea (4.5 mmol/l), serum creatinine (50 mmol/l) and electrolytes were within the normal range. She had no evidence of diabetes mellitus, connective tissue disease, cryoglobulinaemia or any haematological disorder clinically or on laboratory

investigations. There was no family history of similar disease.

With a clinical diagnosis of adult nephrotic syndrome, a renal biopsy was performed. This was sent to the Department of Pathology, University of Malaya Medical Centre for processing and interpretation. The 13 glomeruli identified in the formalin-fixed, paraffin-embedded biopsy specimen showed an eosinophilic material expanding the mesangium and thickening the glomerular capillary walls with segmental accentuation causing partial capillary collapse (Fig. 1). The material was PAS-positive, trichrome green, did not show affinity for Congo red and did not exhibit any natural birefringence. There was no proliferation of glomerular cells. No significant tubular, interstitial or vascular pathology was noted. **Immunofluorescence** examination revealed moderately heavy granular deposits of both C3 and IgG localised predominantly in the glomerular capillary walls with some in the mesangium. No immune deposits were detected in the interstitium, vessel walls or along the tubular basement membrane. Ultrastructural examination was performed on a piece of tissue retrieved from the formalin-fixed, paraffin-embedded tissue block as the renal sample initially fixed in glutaraldehyde for electron

microscopy did not contain any glomeruli. Fibrils measuring 20 nm in diameter in an organised, vaguely microtubular array, were seen predominantly in the subendothelial region (Fig. 2) with some deposition in the mesangium. A histological diagnosis of fibrillary glomerulonephritis was made but this was revised to immunotactoid glomerulopathy after careful review of the electron micrographs.

The patient was referred to the University of Malaya Medical Centre for further management. Repeated serological investigations showed a serum C3 level of 85.7 mg/dl (86.0-184.0 mg/dl) and C4 level of 19.0 mg/dl (20.0-59.0 mg/dl). Antinuclear factor titre was 1:320 with a speckled pattern while anti-DNA antibodies were not detected. Serum electrophoresis re-confirmed that there was no paraproteinemia and immunoglobulin levels were within the normal range. She was commenced on daily prednisolone 60 mg and pravastatin 20 mg. She came with repeated non-specific complaints and increased acne after commencement of treatment. At the end of 8 weeks, no improvement was observed with treatment and prednisolone was tailed down and terminated. At that point, her serum albumin was 16 g/l and fasting cholesterol 11.6 mmol/l. Blood urea, serum creatinine and electrolytes remained in the normal range. She



**FIG. 1:** Photomicrograph showing thickening of glomerular capillary walls and the mesangium by PAS-positive material. There is no associated cellular proliferation. PAS x 100.

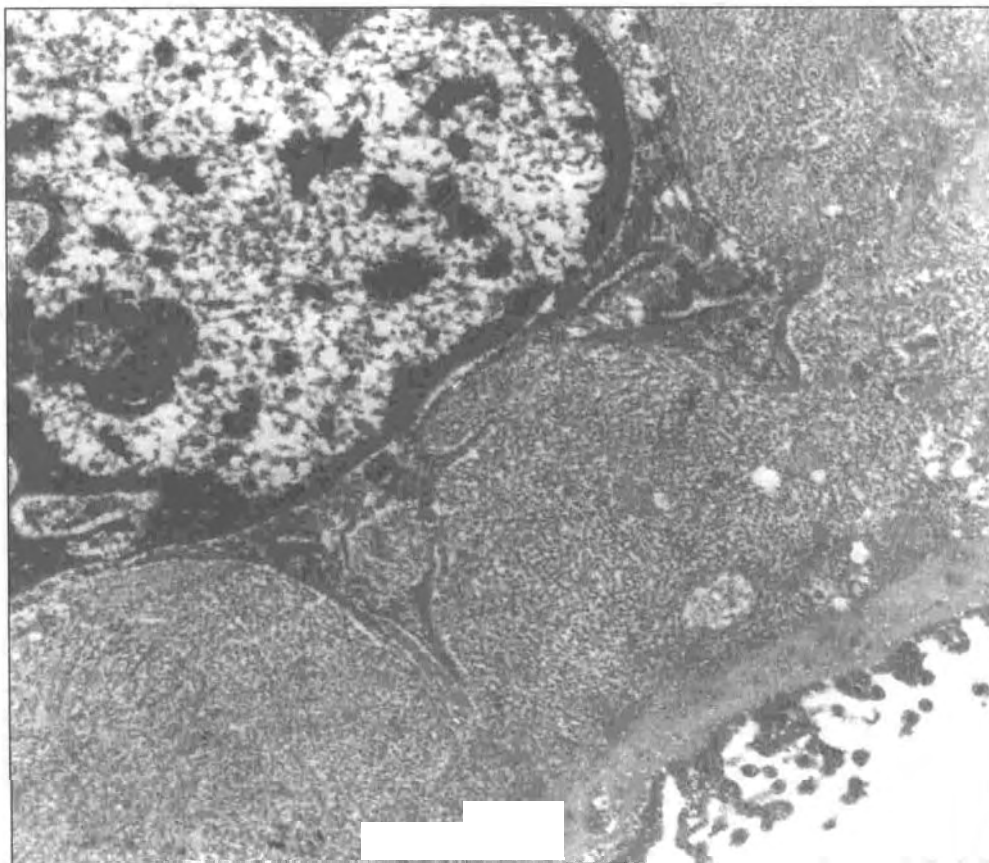


FIG. 2: Electron micrograph showing glomerular subendothelial deposits composed of fibrils with microtubular organisation. TEM  $\times 23,000$ .

was commenced on captopril 6.25 mg twice daily.

She then requested for transfer to another hospital in town for logistic reasons. At that hospital she apparently re-requested for transfer back to the original referring centre. However, she was found later not to have returned to the original referring centre as requested and was lost to follow-up.

## DISCUSSION

Although well recognised as glomerular diseases with fibrillary deposits which are distinct from amyloid,<sup>6</sup> much remains unresolved in ITG and FG. There remains considerable controversy as to whether these entities are distinct from each other.<sup>12</sup> There is suggestion that FG and ITG may be *forme fruste* variants of cryoglobulin- or gammopathy-associated renal diseases.<sup>13</sup> The nature of the fibrils is to date unclear and possible precursor candidates include immunoglobulins,<sup>7-9</sup> fibronectin,<sup>10,11</sup> and type III collagen.<sup>14</sup> As suggested, it is likely that FG and ITG may not

be homogenous conditions and precursors of the fibrillary deposits may not be the same in all cases of FG or ITG.<sup>15</sup>

Although the ultrastructural organisation of the glomerular fibrils in this case would favour its categorisation as immunotactoid glomerulopathy, there are several unusual features. The fibrils, being about 20nm in diameter, place it at the lower range of fibril thickness accepted in ITG. However, electron microscopy was suboptimal in this case because the material for ultrastructural studies was retrieved from the paraffin-embedded biopsy. Hence there would have been some artefactual distortion to the morphology of the fibrils. Clinically, there were some usual features of note. Patients with ITG have been noted to be significantly ( $p < 0.025$ ) older (average age of 62  $\pm$  2 years) at presentation than FG (average age of 50  $\pm$  2 years). Our patient presented at 31-years of age, younger than the average age at presentation for both ITG and FG. However, it is interesting to note that workers have reported

the occurrence of ITG and FG in Asian patients at ages younger than the western average.<sup>14-16</sup> It is also noteworthy that Korbet *et al* showed a significantly higher prevalence of ITG in white compared with black patients.<sup>17</sup> This may imply a genetic influence to the disease. Our patient had no clinically detectable associated haemopoietic disorder. Nonetheless, 67% of ITG patients in one series had an associated haemopoietic disorder compared with 4% of FG cases.<sup>4</sup> The serological results in our patient were not diagnostic of but did not completely exclude an associated systemic lupus erythematosus or other connective tissue disease. However, there were no other features to suggest the presence of any of the above diseases clinically. Nevertheless, there has been a proposal that ITG may be associated with systemic lupus erythematosus based on the ultrastructural finding of fingerprint deposits (not evident in this patient) closely admixed with immunotactoid structures.<sup>18</sup>

Our patient did not respond to 8 weeks of prednisolone therapy. This is in keeping with both FG and ITG where progressive deterioration of renal function appears to be the usual clinical course. Optimal therapeutic regimes in these patients remain uncertain. Long term low dose prednisolone has been suggested by Minami *et al*<sup>19</sup> but renal transplantation appears the most attractive option for patients with end-stage renal disease.<sup>1</sup>

## ACKNOWLEDGMENT

We are grateful to Professor Arthur Cohen of University of California Los Angeles for confirming our histological diagnosis.

## REFERENCES

- Rosenmann E, Eliakim M. Nephrotic syndrome associated with amyloid-like glomerular deposits. *Nephron* 1977; 18: 301-8.
- Schwartz MM, Lewis EJ. The quarterly case: Nephrotic syndrome in a middle-aged man. *Ultrastruct Pathol* 1980; 1:575.
- Alpers CE. Immunotactoid (microtubular) glomerulopathy: an entity distinct from fibrillary glomerulonephritis? *Am J Kidney Dis* 1992; 19:185-91
- Fogo A, Qureshi N, Horn RG. Morphologic and clinical features of fibrillary glomerulonephritis versus immunotactoid glomerulopathy. *Am J Kidney Dis* 1993; 22: 367-77.
- Pronovost PH, Brady HR, Gunning ME, Espinoza O, Rennke HG. Clinical features, predictors of disease progression and results of renal transplantation in fibrillary/immunotactoid glomerulopathy. *Nephrol Dial Transplant* 1996; 11:837-42.
- Looi LM. Amyloids and tactoids. *J Pathol* 1993; 170:417-8.
- Iskandar SS, Falk RJ, Jennette JC. Clinical and pathologic features of fibrillary glomerulonephritis. *Kidney Int* 1992; 42:1408-7.
- Monga G, Mazzucco G, Motta M, Quaranta S. Immunotactoid glomerulopathy (ITGP): a not fully defined clinicopathologic entity. *Ren Fail* 1993; 15:401-5.
- Esparza AR, Chazan JA, Nayak RN, Cavallo T. Fibrillary (immunotactoid) glomerulopathy. A possible role for kappa light chain in its etiology and/or pathogenesis. *Am J Surg Pathol* 1991; 15:632-43.
- Mazzucco G, Maran E, Rollino C, Monga G. Glomerulonephritis with organized deposits: a mesangiopathic, not immune complex-mediated disease? A pathologic study of two cases in the same family. *Hum Pathol* 1992; 23:63-8.
- Assmann KJ, Koene RA, Wetzels JF. Familial glomerulonephritis characterised by massive deposits of fibronectin. *Am J Kidney Dis* 1995; 25:781-91.
- Ikeda K, Yokoyama H, Tomosugi N, Kida H, Ooshima A, Kobayashi K. Primary glomerular fibrosis: a new nephropathy caused by diffuse intra-glomerular increase in atypical type III collagen fibres. *Clin Nephrol* 1990; 33:155-9.
- Churg J, Venkateshan VS. Fibrillary glomerulonephritis without immunoglobulin deposits in the kidney. *Kidney Int* 1993; 44:837-42.
- Wang S, Zhang Y, Zou W. Immunotactoid glomerulopathy. *Chung Hua I Hsueh Tsa Chih* 1996; 76:688-90.
- Takemura T, Yoshioka K, Akano N, Michihata I, Okada M, Maki S, Shigematsu H. Immunotactoid glomerulopathy in a child with Down syndrome. *Pediatr Nephrol* 1993; 7:86-8.
- Chung WY, Lee SY, Joo JE. Fibrillary glomerulonephritis in a 9-year-old girl. *Nephron* 1995; 69:79-82.
- Korbet SM, Genchi RM, Borok RZ, Schwartz MM. The racial prevalence of glomerular lesions in nephrotic adults. *Am J Kidney Dis* 1996; 27:647-51.
- Lai FM, Lai KN, Li EK, Sung JY, Tam JS. Immunotactoid glomerulopathy with fingerprint immune deposits. A variant of lupus nephritis? *Virchows Arch A Pathol Anat Histopathol* 1989; 415:181-6.
- Minami J, Ishimitsu T, Inenaga T, Ishibashi-Ueda H, Kawano Y, Takashita S. Immunotactoid glomerulopathy: a report of a case. *Am J Kidney Dis* 1997; 30:160-3.