

## Serum ferritin and lactate dehydrogenase in a case of hemophagocytic lymphohistiocytosis

C F Leong, MD, S K Cheong, FRCP, FRCPA, NH Hamidah, MBChB, DCP, O Ainoon, MBBS, DCP, and Y Kannaheswary, DCH, MRCP\*

Departments of Pathology and Paediatrics\*, Faculty of Medicine, University Kebangsaan Malaysia, Kuala Lumpur.

### Abstract

A 40-day-old baby girl presented with intermittent fever, lymphadenopathy, massive hepatosplenomegaly, progressive pancytopenia and features of disseminated intravascular coagulopathy. A bone marrow aspiration was performed and showed florid histiocytic proliferation with marked hemophagocytosis. Based on the diagnostic guideline for Hemophagocytic Lymphohistiocytosis proposed by the Familial Hemophagocytic Lymphohistiocytosis Study Group of Histiocyte Society, this patient has fulfilled most of the criteria. We have also found that serum ferritin and lactate dehydrogenase to be very high in this patient. It remains uncertain whether the disorder is reactive or neoplastic.

**Key words:** Hemophagocytosis, pancytopenia, ferritin, lactate dehydrogenase

### INTRODUCTION

Hemophagocytic lymphohistiocytosis (HLH) is a rare disorder with an incidence rate of 1-2 cases per million per year.<sup>1</sup> It is characterized by inappropriate activation of the mononuclear phagocyte system<sup>1,2,3</sup> with excessive production of cytokines.<sup>4</sup> The first publication describing this lethal syndrome in a family was by Farquhan and Clarreux.<sup>2</sup> The Familial Histiocytic Lymphohistiocytosis Study Group of Histiocyte Society has outlined a diagnostic guideline for HLH, which includes the clinical, laboratory and histology findings. The principal features are idiopathic fever, massive hepatosplenomegaly, cytopenias, hypertriglyceridemia, hypofibrinogenemia and disseminated proliferation and activation of histiocytes with varying degrees of hemophagocytosis in different organs.<sup>1,3,5</sup> Elevated serum ferritin and blood level of lactate dehydrogenase (LDH) were reported in many cases.<sup>3,6</sup> Therefore, hyperferritinemia and elevated serum LDH may serve as additional diagnostic parameters for HLH. We report the findings of such a case.

### CASE REPORT

A 40-day-old Malay infant was referred from a district hospital with a history of intermittent fever for 10 days, associated with left axillary

lymphadenopathy and gross hepatosplenomegaly. No family history of similar illness was elicited. On admission, the patient was febrile with a temperature of 38°C. She was pale and mildly jaundiced, but with no dysmorphic facies. She was tachypneic but not in acute distress. A left axillary lymph node was found to be enlarged measuring 3 x 2 cm. The liver and the spleen were 8 cm and 5 cm below the respective costal margins. Systemic review was non-contributory.

Laboratory investigations revealed Hb: 7.4g/dl, Hct: 23.8, Leukocytes:  $2.4 \times 10^9/L$  (neutrophils:  $0.6 \times 10^9/L$ ) and Platelet:  $22 \times 10^9/L$ . The ESR was 8mm/hour. Liver profile showed hypoalbuminemia (29g/L) with conjugated hyperbilirubinemia and raised liver enzymes (ALT 244mmol/L, AST 279 mmol/L). Coombs' test was negative. Chest X-ray showed features of pneumonia with mild right sided pleural effusion. Ultrasound of the abdomen showed hepatosplenomegaly with mild ascites. 2D Echocardiogram showed a normal function heart with a thin rim of pericardial effusion posteriorly. Septic workup, TORCHES screening, Hepatitis B/C and HIV screening were all negative. Investigations for metabolic disorders were uneventful. Serum triglyceride: 1.69 mmol/L, serum ferritin: 25534 mg/L and serum LDH:

19575 IU/L. Her coagulation profile showed features of disseminated intravascular coagulopathy and her serial blood counts were persistently pancytopenic. A bone marrow aspiration showed **normocellular** to hypercellular fragments and cell trails, both erythropoiesis and granulopoiesis were normal, megakaryocytes were plentiful; there were hyperplasia of histiocytes with marked hemophagocytosis (Figs. 1,2 & 3) and atypical lymphocytosis. (Figs. 3 & 4) A final diagnosis of Hemophagocytic lymphohistiocytosis (HLH) was made. Unfortunately, the patient expired 2 days after the diagnosis at the age of 57 days.

**DISCUSSION**

The diagnosis is frequently delayed due to the absence of useful diagnostic marker. The Familial Histiocytic Lymphohistiocytosis Study Group of the Histiocyte Society has proposed a

diagnostic guideline for HLH to facilitate the diagnosis (Table 1).<sup>5</sup> Various studies have demonstrated that fever (>90%), hepatosplenomegaly (>84%) and cytopenias (96%) were the most frequently noted **findings**.<sup>1,3,5</sup> Hypertriglyceridemia (80%) and hypofibrinogenemia (74%) were less often seen. In our patient, she has fulfilled most of the clinical and laboratory criterias, and we have also found that her serum ferritin (**25534mg/L**) and blood LDH (**19575iu/L**) were extremely high. This is in agreement with a study done in Japan by **Imashuku et al**,<sup>3</sup> in which they have noted that serum ferritin and lactate dehydrogenase (LDH) are both elevated in the majority of their cases. The incidence of hyperferritinemia > **1000 mg/L** and elevated blood LDH level > **1000 IU/L** was much higher than that of hypertriglyceridemia and hypofibrinogenemia (i.e. 90% & 89.7% Vs 50% & **57.4**).<sup>3</sup> Koduri et al<sup>6</sup> has also reported similar

TABLE 1: Diagnostic Guidelines for Hemophagocytic Lymphohistiocytosis

---

Clinical and Laboratory Criteria

- Fever (duration 2 7 days, with peaks 2 38.5°C)
- Splenomegaly (2 3 cm below the costal arch)
- Cytopenia (affecting 2 2 of 3 lineages in the peripheral blood and not caused by a hypocellular or dysplastic bone marrow):
  - Hemoglobin < 90 g/l
  - Platelets < 100x10<sup>9</sup>/l
  - Neutrophils < 1.0x10<sup>9</sup>/l
- Hypertriglyceridemia and / or **hypofibrinogenemia** (fasting triglycerides ≥ 2.0mmol/l or 2 3 SD of the normal value for age, fibrinogen E 1.5g/l or £ 3 SD)

**Histopathological** Criteria

- Hemophagocytosis in bone marrow or spleen or lymph nodes. No evidence of malignancy.

---

Hemophagocytic Lymphohistiocytosis (HLH)

All the above criteria are required for the diagnosis.

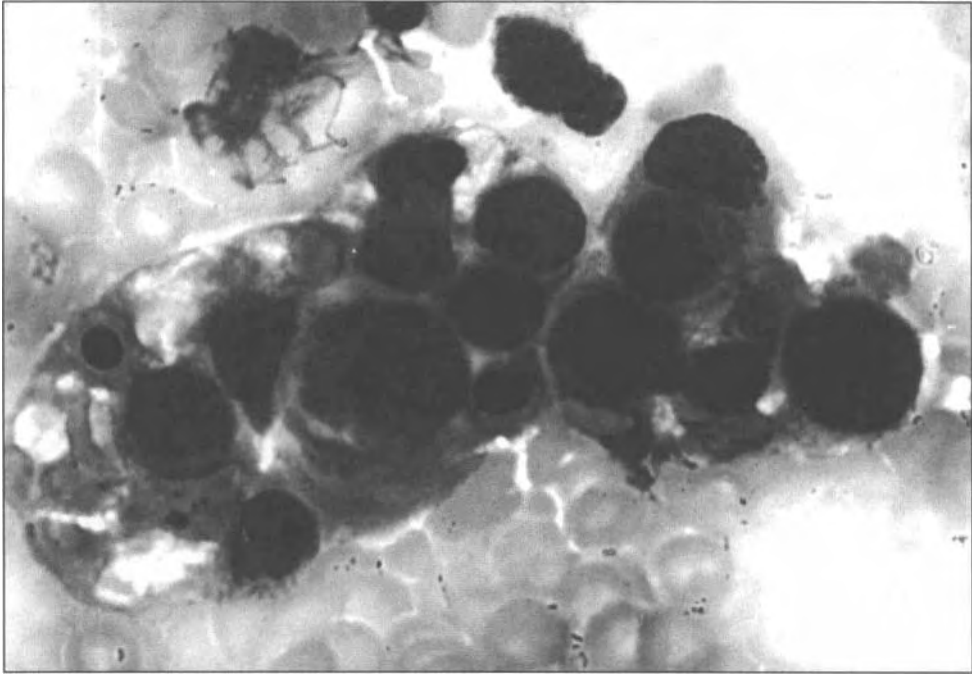
Familial Hemophagocytic **Lymphohistiocytosis** (FHL)

The diagnosis **FHL** is justifying in the presence of a family history of HLH and all criteria listed above. Parental consanguinity is suggestive of **FHL**.

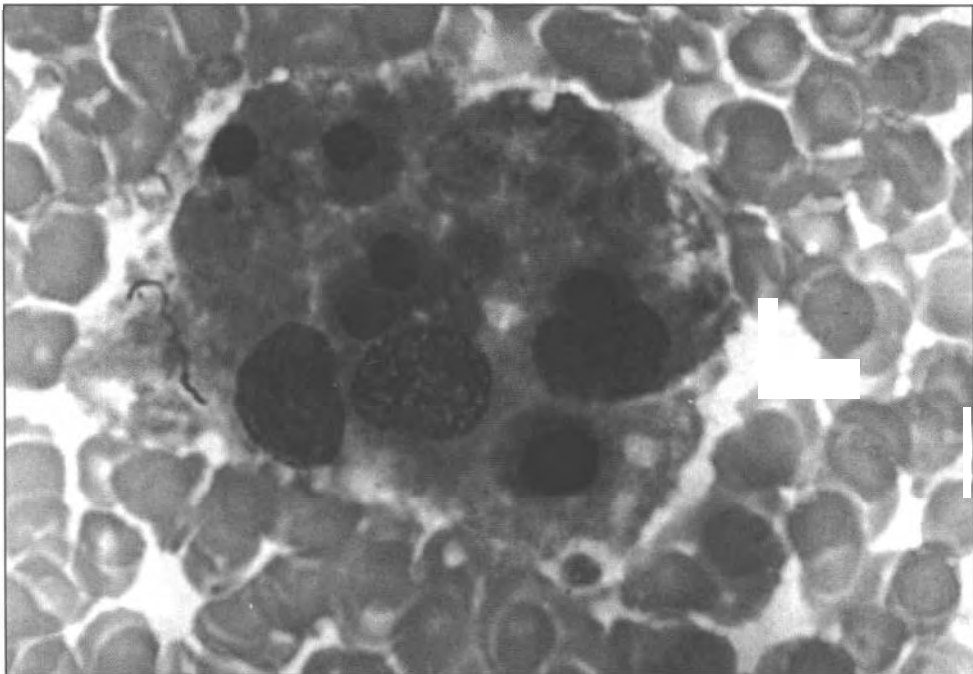
---

Comments:

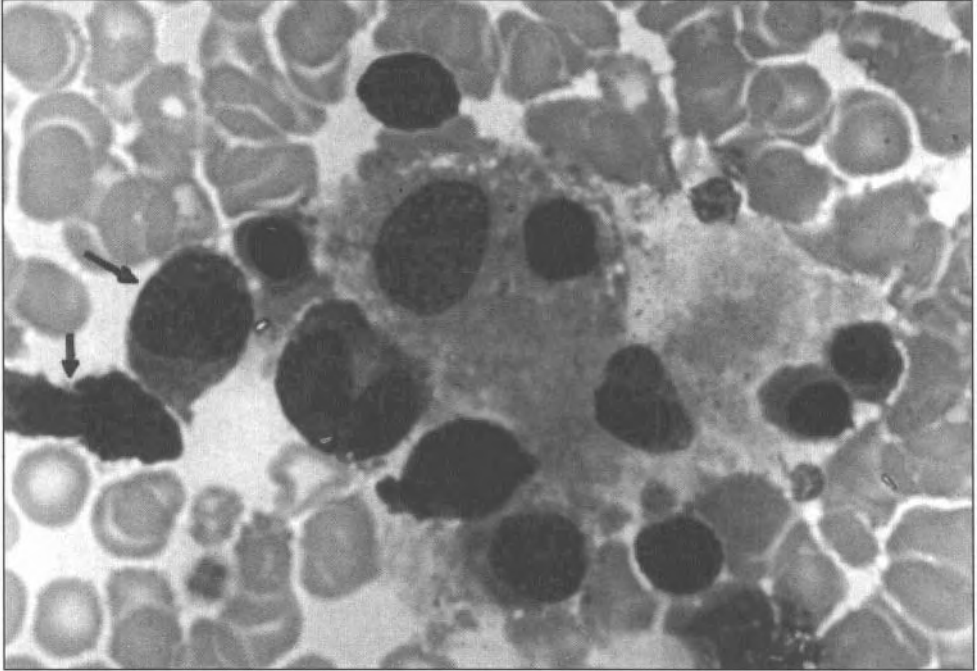
1. If **hemophagocytic** activity is not proven at the time of presentation, further search for hemophagocytosis is encouraged. If the bone marrow specimen is not conclusive, material should be obtained from other organs, especially lymph nodes or spleen. Serial marrow aspirates over time may also be helpful.
2. The following findings may provide strong supportive evidence for the diagnosis : a) Spinal fluid pleocytosis (frequently < 50x10<sup>6</sup> cells/l; mainly mononuclear cells); b) Histological picture in the liver resembling chronic persistent hepatitis; and c) low natural killer cell activity.
3. Other abnormal clinical and laboratory findings in HLH, not listed above, may be : lymph node enlargement, skin rash, **cerebro-meningeal** symptoms, jaundice, edema-- especially periorbital, increased spinal fluid protein content, elevated levels of **transaminases**, hypoproteinemia, hyponatremia, increased very low density lipoproteins and decreased high density lipoproteins. Hyperferritinemia and increased number of soluble interleukin-2 receptor have recently been reported.



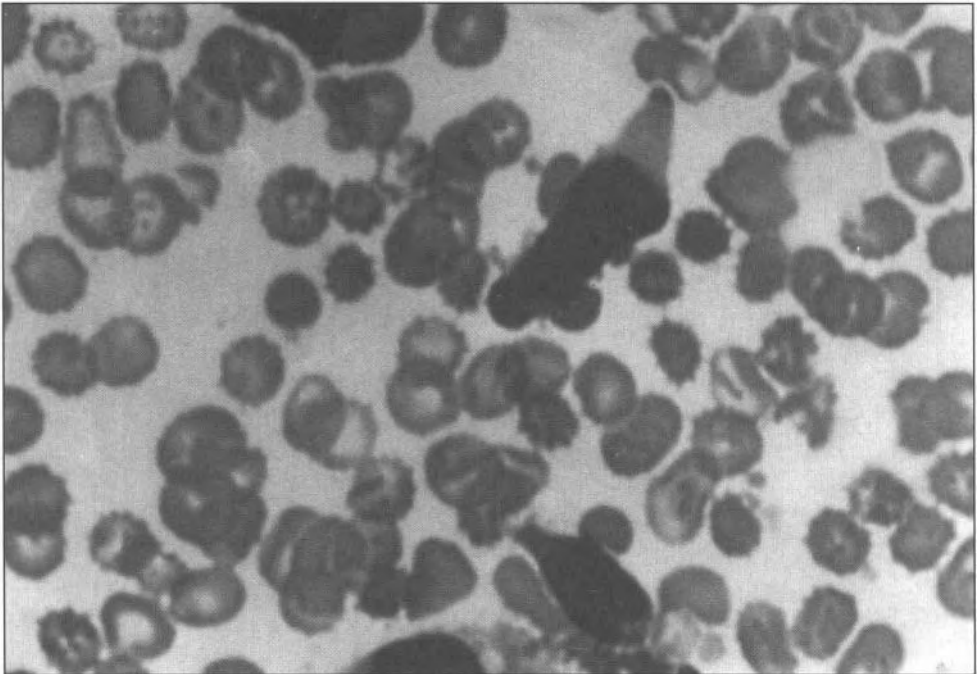
**FIG. 1:** Photomicrograph of histiocytes ingesting hemopoietic cells of various lineages. MGG X 100.



**FIG. 2:** Three histiocytes engulfing nucleated red cells, erythrocytes and megakaryocyte fragments. MGG X 100.



**FIG. 3: Hemophagocytosis with some atypical lymphocytes (arrows). MGG X 100.**



**FIG. 4: A few atypical lymphocytes seen in the bone marrow. MGG X 100.**

findings in all his 4 cases (Table 1). Esumi *et al*<sup>7</sup> has suggested serum **ferritin** as an useful indicator of disease activity in histiocytic proliferative disorder. Matzner *et al*<sup>8</sup> has also found that serum ferritin is related to the tumor histology, the level being highest in histiocytic lymphoma and Hodgkin's disease.

The pathophysiology of HLH is thought to be due to the deregulation of T lymphocytes and excessive production of **cytokines**<sup>4,9</sup> including interferon- $\gamma$  (IFN- $\gamma$ ) and interleukin-2 (IL-2). IFN- $\gamma$  is known to stimulate macrophages to induce rapid production of IL-1, tumor necrosis factor- $\alpha$  (TNF- $\alpha$ ), IL-10 and IL-12.<sup>9</sup> IL-1 and TNF- $\alpha$  have been demonstrated by Tue N. Tran *et al*<sup>10</sup> to double the amount of femtin release by rat hepatic cells in vitro. Lee *et al*<sup>11</sup> has suggested that IL-1 produced by mononuclear cells may possibly facilitate a shift of iron stores from transferrin bound state to femtin bound state. We believe that this could be the mechanism leading to hyperfemtinemia in this patient. Moreover, marked erythrophagocytosis by the histiocytes in HLH increases the red cell turnover, hence resulting in increased iron release into the circulation. Enhanced iron flux has also been demonstrated to increase serum **ferritin** level, which may contribute further to the high serum femtin level.<sup>10</sup>

The other parameter that was proposed to be of help in the diagnosis of HLH is serum LDH level. LDH is a cytoplasmic cellular enzyme that will be released into the extracellular space in pathological conditions such as cell damage or inflammation. Patel *et al*<sup>12</sup> and Csako *et al*<sup>13</sup> has respectively reported the usefulness of serum LDH for the diagnosis, treatment monitoring in patients with leukemia and American Burkitt's lymphoma. HLH is characterized by hyperplasia of the histiocytes, which are actively engulfing hematopoietic cells. This marked hemophagocytosis may result in massive cell damage and subsequently release of large amount of LDH into the circulation.

Although both the serum femtin and serum LDH are not specific and increased level may be present in many other conditions, the extremely high levels are very striking and may serve as important clues for the diagnosis of HLH.

A previous study<sup>14</sup> has failed to demonstrate clonal chromosome abnormalities in their patients suggesting that HLH is a non-neoplastic disease. Favara<sup>15</sup> and Smith *et al*<sup>16</sup> believe that the phagocytic histiocytes are ordinary reactive histiocytes of mononuclear phagocytic system, stimulated by either T lymphocytes which is

neoplastic or in response to viral infection or due to **cytokines** produced by proliferating T lymphocytes and / or reactive phagocytic histiocytes. However, the fact that many HLH patients died early of progressive disease, infections or multiple organ failure with a reported overall mortality of 74%,<sup>1</sup> the response of some patients to cytotoxic chemotherapy as well as the increased 5-year survival rate to 66% in patients undergone allogeneic bone marrow transplant may indicate that the disease is neoplastic rather than reactive. T-cell receptor rearrangement<sup>11</sup> as well as chromosome abnormalities<sup>18</sup> have been reported in some patients with HLH. However, the evidence of clonality which denotes neoplasia in these reports are not convincing and it remains uncertain whether HLH is neoplastic or reactive.

## REFERENCES

1. Harst SJR, Layton DM, Singh S, Mielli-Vergani G, Chessells JM. Haemophagocytic lymphohistiocytosis: experience at two U.K. centers. *Br J Haematol* 1994; 88: 731-9.
2. Filipovich, Alexandra H. Hemophagocytic lymphohistiocytosis: A lethal disorder of immune regulation. *J Pediatrics* 1997; 130 (3): 337-8.
3. Shinsaku I, Shigeyoshi H, Shinjiro T. Hemophagocytic lymphohistiocytosis in infancy and childhood. *J Pediatrics* 1997; 130 (3): 352-7.
4. Fl'echaire A, Colle B, Bernard P, Dupuy O, Pilippe P. Hemophagocytic syndromes. [Abstract]. *Rev Med Interne (French)* 1996; 17 (2): 157-62.
5. Jan-Inge Henter, Goran Elinder, Ake Ost and the FHL Study Group of the Histiocyte Society. Diagnostic Guidelines for Hemophagocytic Lymphohistiocytosis. *Sem Oncol* 1991; 18: 29-33.
6. Koduri PR, Carandang G, DeMarais P, Patel AR. Hyperferritinemia in reactive hemophagocytic syndrome report of four adult cases. *Am J Hematol* 1995; 49 (3): 247-9.
7. Esumi N, Ikushima S, Hibi S, Todo S, Imashuku S. High serum femtin level as a marker of malignant histiocytosis and virus-associated hemophagocytic syndrome. *Cancer* 1988; 61 (10): 2071-6.
8. Matzner Y, Konijn AM, Hershko C. Serum femtin in hematologic malignancies. *Am J Hematol* 1980; 9 (1): 13-22.
9. Yuko O, Junichi H, Shiiichi T et al. Cytokine production regulating Th1 and Th2 cytokines in hemophagocytic lymphohistiocytosis. *Blood* 1997; 81 (11): 4100-3.
10. Tran TN, Eubanks SK, Schaffer KJ, Zhou CYJ, Linder MC. Secretion of femtin by rat hepatoma cells and its regulation by inflammatory cytokines and iron. *Blood* 1997; 90 (12): 4979-86.
11. Lee MH, Means RT. Associated disease and clinical significance (Extremely elevated serum ferritin levels in a university hospital). *Am J Med* 1995; 98 (6): 566-71.
12. Patel PS, Adhvaryu SG, Balar DB. Serum lactate

- dehydrogenase and its **isoenzymes** in leukemia patients: possible role in diagnosis and treatment monitoring. *Neoplasma* 1994; 41 (1): 55-59.
13. **Csako G**, Magrath IT, Elin RJ. Serum total and isoenzyme lactate dehydrogenase activity in American **Burkitt's** lymphoma patients. *Am J Clin Pathol* 1982; 78 (5): 712-7.
  14. **Kletzel M**, Gollin SM, Gloster ES, Jimenez JF, **Golladay ES**, **Berry DH**. Chromosome abnormalities in familial hemophagocytic lymphohistiocytosis. *Cancer* 1986; 57 (11): 2153-7.
  15. Favara BE. Hemophagocytic lymphohistiocytosis: a hemophagocytic syndrome. *Sem Diag Pathol* 1992; 9 (1): 63-74.
  16. Smith KJ, Skelton HG, **Yeager J** et al. Cutaneous **histopathologic, immunohistochemical**, and clinical manifestations in patients with hemophagocytic syndrome. Military medical consortium for applied retroviral **research.(MMCARR)**. *Arch Dermatol* 1992; 128 (2): 193-200.
  17. Owen G, **Webb**. Evidence of clonality in a child with hemophagocytic lymphohistiocytosis (Short report). *Br J Haematol* 1995; 98 (3): 681-2.
  18. **Yasuhiko K**, Nobuo M, **Masaharu S** et al. Clonal and non-clonal karyotypically abnormal cells in haemophagocytic lymphohistiocytosis. *Br J Haematol* 1995; 90: 48-55.