

## Incidence of acute atherosclerosis in complete molar pregnancy

Hayati AR MBChB, DCP, \*Azizah A MBBS, \*Wahidah A MBChB, MPath

Department of Pathology, Universiti Kebangsaan Malaysia and \*Department of Pathology, Hospital Kuala Lumpur

### Abstract

A clinicohistological study of acute atherosclerosis in molar pregnancy was undertaken. Maternal decidual vessels in **curettag**e samples of 38 histologically confirmed complete hydatidiform moles were examined histologically for acute atherosclerosis, recognised as fibrinoid necrosis of the smooth muscle wall with a perivascular mononuclear cell infiltrate, with or without lipophages. Acute atherosclerosis was detected in eight of 38 cases, an incidence of 18.4%. **All** the patients were normotensive. The significance of acute atherosclerosis in molar pregnancy remains to be clarified.

**Key words:** Molar pregnancy, maternal decidual vessels, acute atherosclerosis.

### INTRODUCTION

The **occurrence** of acute atherosclerosis in preeclampsia is well **accepted**<sup>1,2,3</sup> and it has also been described in various pregnancy **disorders**.<sup>2,4</sup> Since hydatidiform mole is a common and important complication of pregnancy, the incidence in Malaysia being 1: **669**,<sup>5</sup> we endeavoured to study the coexistence of acute atherosclerosis in this pregnancy disorder. To the best of our knowledge, this study is the first to examine this association.

### MATERIALS AND METHODS

Sixty cases of molar pregnancy diagnosed histologically at the Department of Pathology, Hospital Kuala Lumpur over a 2-year period were retrieved from the files. All histological sections from these cases were reviewed. Patient data were analysed to exclude patients with preexisting diabetes mellitus, essential hypertension and systemic lupus erythematosus. Thirty-eight cases were included in this study after histologically reconfirming the diagnosis of complete hydatidiform mole and the presence of maternal decidual vessels in the hematoxylin and eosin sections. This study was focused on the absence or presence of acute atherosclerosis in the maternal decidual vessels. Acute atherosclerosis was defined as fibrinoid necrosis of the arterial smooth muscle wall accompanied by lipid-laden macrophages and a perivascular round cell **infiltrate**.<sup>2,6</sup>

### RESULTS

Acute atherosclerosis was seen in eight out of the 38 cases, an incidence of 18.4%. In established acute atherosclerosis, a perivascular mononuclear cell infiltrate and lipophages within the vessel wall that had been destroyed by fibrinoid necrosis were seen (Fig. 1). In others, there were no lipophages present. All the eight cases with acute atherosclerosis were normotensive women.

### DISCUSSION

Acute atherosclerosis is not seen in normal **pregnancies**.<sup>4</sup> Several investigators have described acute atherosclerosis in pregnancies complicated by pre-eclampsia, small-for-gestational-age, diabetes mellitus and systemic lupus **erythematosus**.<sup>2,4,7,8,9</sup> Differences in the definition of the lesion has led to the controversy regarding the presence or absence of acute atherosclerosis in the various pregnancy disorders. In this present study, the maternal decidual vessels show fibrinoid necrosis, which is the earliest lesion that can be confidently identified on light microscopical **examination**,<sup>2,10</sup> and perivascular mononuclear cell infiltrate with or without lipophages. Since there are no prior studies on acute atherosclerosis in molar pregnancies, a comparison of our findings with those of others cannot be made. The incidence of acute atherosclerosis in this study is comparable to a 22% incidence of acute atherosclerosis in mild pre-eclampsia observed by **Moque et al.**<sup>11</sup> However the cause of acute

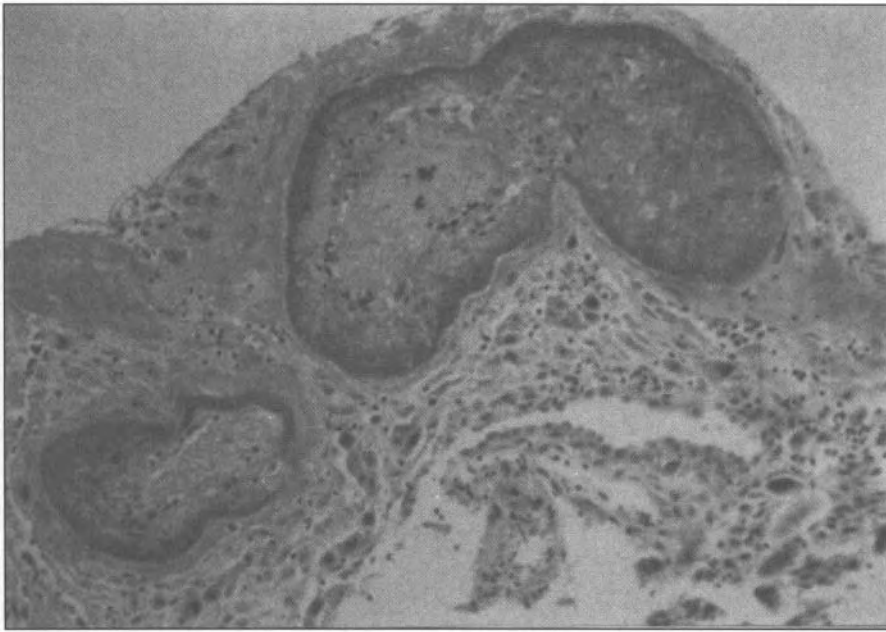


FIG. 1: Photomicrograph of maternal decidual vessels exhibiting fibrinoid necrosis of the smooth muscle, lipid-laden macrophages and a perivascular round vessel infiltrate. H&E x 100.

atherosis in our 8 cases cannot be attributed to pre-eclampsia as all were normotensive. Furthermore, hypertension alone does not cause acute atherosclerosis.<sup>3,12</sup> It may be that an inappropriate immunological foetomaternal reaction may be the major determinant of acute atherosclerosis<sup>4,6,13</sup> or it may be an unusual response to placentation expressed by a particular HLA type. However further detailed studies are required, including HLA typing of the father or mother before the pathophysiology of acute atherosclerosis can be understood.

## REFERENCES

1. Meekins JW, Pijnenborg R, Hassens M, McFadyen IR, Van Assche A. A study of placental bed artery and trophoblast invasion in normal and severe pre-eclamptic pregnancies. *Br J Obstet and Gynaecol* 1994; 101: 669-74.
2. Khong TY. Acute atherosclerosis in pregnancies complicated by hypertension, small for gestational age infants and diabetes mellitus. *Arch Pathol Lab Med* 1991; 115: 722-5.
3. Khong TY, Pearce JM, Robertson WB. Acute atherosclerosis in preeclampsia: maternal determinants and fetal outcome in the presence of the lesion. *Am J Obstet Gynaecol* 1987; 157 (2): 360-7.
4. Nayar R, Lage JM. Placental changes in a first trimester missed abortion in maternal systemic lupus erythematosus with antiphospholipid syndrome: A case report and review of the literature. *Hum Pathol* 1996; 27(2): 201-6.
5. Ong HC, Lee P, Ng TKF *et al.* Clinical observations of hydatidiform moles in Malaysian hospital. *Singapore Med J* 1976; 19: 33-6.
6. Labarrere CA. Acute atherosclerosis. A histopathological hallmark of immune aggression? *Placenta* 1988; 9:95-108.
7. Kitzmiller JL, Watt N, Driscoll SG. Decidual arteriopathy in hypertension and diabetes in pregnancy: Immunofluorescent studies. *Am J Obstet Gynaecol* 1981; 141:773-9.
8. Driscoll S. The pathology of pregnancy complicated by diabetes mellitus. *Med Clin North Am* 1965; 49:1053-67.
9. Abramowsky CR, Veges ME, Swinehart G *et al.* Decidual vasculopathy of the placenta in lupus erythematosus. *N Engl J Med* 1980; 303:668-72.
10. De Wolf F, Robertson WB, Brosens I. The ultrastructure of acute atherosclerosis in hypertensive pregnancy. *Am J Obstet Gynaecol* 1975; 123:164-74.
11. Moque M, Azuela CJ, de la Vega MD. Placental pathology in eclampsia and preeclampsia. *Obstet Gynaecol* 1964; 24: 350-6.
12. De Wolf F, Robertson WB, Brosens I. The ultrastructure of acute atherosclerosis in hypertensive pregnancy. *Am J Obstet Gynaecol* 1975; 123(2):164-74.
13. Robertson WB, Brosens I, Dixon G. Uteroplacental vascular pathology. *Eur J Obstet Gynaecol Reprod Biol* 1975; 5: 47-65.