

## Tumours and tumour-like lesions of the eye: A clinicopathological study from Hospital University Sains Malaysia

S C REDDY, MS (Ophth), FICS. and \*P K DAS, MD , FRCPA

Departments of Ophthalmology and \*Pathology, School of Medical Sciences, University Sains Malaysia, Kubang Kerian, Kelantan, Malaysia.

### Abstract

A total of 89 histopathologically proven ocular tumours and tumour-like lesions treated in Hospital University Sains Malaysia, Kubang Kerian, Kelantan over a period of nine years were reviewed for their age distribution, site of lesion and histological type. The tumours were observed in all age groups with a maximum prevalence in the first decade. Twenty lesions were malignant and 69 were benign. The eyelid was the most frequent location (51%), followed by the conjunctiva (32%). Retinoblastoma was the most common malignant tumour (10 cases) and dermoid cyst was the most common tumour-like lesion (16 cases).

*Key words:* Ocular tumours, retinoblastoma, orbital tumours.

### INTRODUCTION

Tumours of the eye can be extraocular or intraocular. Extraocular tumours arise from the conjunctiva (epibulbar) or from the eyelids, lacrimal gland and contents of the orbit (adnexal).

Intraocular tumours arise from the iris, ciliary body, choroid or retina. Either categories can be benign or malignant and occur in any age group. Benign lesions and extraocular tumours are seen more frequently in clinical practice than malignant and intraocular tumours. Benign lesions are removed mainly for cosmetic reasons. Early surgical intervention in malignant tumours will prevent their spread to adjacent structures in the eye which can result in functional disability.

A literature search did not reveal any data on the epidemiology of ocular tumours from Malaysia even though such reports are available from other countries. The present study was carried out to provide baseline data on the prevalence of tumours and tumour-like lesions of the eye and the patients' compliance towards therapy in East coast Malaysia, where Hospital University Sains Malaysia (HUSM) is located in a rural set-up. The present study is an analysis of histopathologically proven ocular growths treated over a period of nine years (1985-1993). It is a retrospective study of the first six years and a prospective study of the subsequent three years.

### MATERIALS AND METHODS

Case records of patients attending the department of Ophthalmology, HUSM with a history of growth in the eye or eyelids, protrusion of eyeball and white reflex in the pupillary area were reviewed. The growth was surgically removed *in toto* in most of the cases. However, in a few cases where such resection was not possible, biopsy was taken. All the specimens were sent in 10% buffered formalin solution to the department of Pathology for histopathological examination. The specimens were processed routinely and sections were stained with haematoxylin and eosin. Special stains and immunohistochemical staining for cytokeratin, epithelial membrane antigen, S-100, vimentin, leucocytic common antigen etc. were done when required. The tumours of the eye and adnexa were classified as surface epithelial, glandular, mesenchymal, pigmented, neural, developmental and reticulosis tumours according to the W.H.O. classification. Non neoplastic tumour-like lesions were included under benign growths.

### RESULTS

A total of 89 ocular tumours and tumour-like lesions were encountered during this period. Forty-six of these occurred in males and 43 in females. The growths were observed in all age groups, with the maximum number in the first

**TABLE 1: Sex and age distribution of patients with tumour and tumour-like lesions of the eye.**

Age in years	Male (n=46)	Female (n=43)	Total (n=89)
Up to 10	13	9	22
11 - 20	9	7	16
21 - 30	3	9	12
31 - 40	7	3	10
41 - 50	6	5	11
51 - 60	5	3	8
61 - 70	-	6	7
71 - 80	3	1	4

decade (Table 1). The youngest patient was 3 months old and the oldest aged 73 years. Of 89 growths, 20 were malignant and 69 were benign. Half of these lesions (51%) occurred in the eyelids (Table 2). Of the benign lesions, 54 were non neoplastic tumour-like lesions: 24 of these were cystic lesions while the remaining were solid. The most frequently observed benign growth was dermoid cyst and the most common malignant tumour was retinoblastoma (Table 3). Twenty-one out of 89 ocular growths were seen in children aged 12 years or below: 10 of these were malignant (retinoblastoma) and 11 were benign. Eight of the benign lesions in children were in the eyelids (dermoid cyst 5, capillary haemangioma 3) and three were in the conjunctiva (limbal dermoid 2, choristoma 1).

**Benign lesions**

In the present study *dermoid cyst* was the most frequently observed benign growth (Table 3). All the dermoids of the eyelids were located near the outer *canthus* of the upper lid. These were small and cystic in nature. Histologically, the cyst was lined by a layer of stratified squamous epithelium. The wall of the cyst contained hair follicles and sebaceous glands

and the cavity contained flakes of keratin. None of these lesions had any extension into the orbit. *Dermoid* of the conjunctiva occurred as a smooth, round, elevated, solid growth near the limbus in the interpalpebral area on the medial side. In one case, the lesion was seen in both eyes as part of Goldenhar syndrome in a five-year-old boy.

The next most common benign tumour was the *naevus* (13 cases): 7 occurred in the eyelid and 6 in the conjunctiva. These were seen as pigmented elevated lesions. Even though these were very small (4-6mm) surgical excision was done for cosmetic reasons. Histologically the lesions consisted of clusters of naevus cells grouped under the surface epithelium with no **junctional** activity. The cells have abundant cytoplasm and a large round nucleus. Some of the cells contain melanin pigment (Fig 1).

*Pyogenic granuloma* was seen in eight patients (five following chalazion surgery and three following pterygium surgery) in our study. Histologically these lesions were made up of numerous endothelial-lined capillary spaces separated by connective tissue stroma (typical appearance of capillary haemangioma) with evidence of ulceration and inflammation.

**TABLE 2: Prevalence of benign and malignant tumours in different parts of the eye**

Location	Benign (n=69)	Malignant (n=20)	Total (n=89)	Percentage
Eye lids	40	5	45	51 %
Conjunctiva	26	2	28	32 %
Retina		10	10	11 %
Lacrimal gland	3	-	3	3 %
Orbit		3	3	3 %

**TABLE 3: Histological types of tumour and tumour-like lesions of the eye .**

Histological type	Eye lid (n=45)	Conjunctiva (n=28)	Retina (n=10)	Orbit (n=3)	Lacrimal gland (n=3)
<b>Malignant tumours:</b>					
Basal cell carcinoma	3	-			
Squamous cell carcinoma	1	1			
Malignant melanoma	1	1	-		-
Retinoblastoma			10		
Meningioma			-	1	-
Non-Hodgkin's lymphoma				2	-
<b>Benign tumours:</b>					
Papilloma	3	1	-	-	
Lipoma	2	1	-	-	
Haemangioma	2		-	-	
Keratoacanthoma	1		-	-	-
Pleomorphic adenoma			-	-	2
Adenoma			-	-	1
<b>Tumour like lesions:</b>					
<b>Dermoid cyst</b>	13	3	-		-
Epidermal cyst	4	-	-		-
Sudoriferous cyst	1	-	-		-
<b>Epithelial inclusion cyst</b>		5	-		-
Epidermal cyst <b>caruncle</b>	-	1	-		-
Naevus	7	6	-		-
Xanthelasma	2		-		-
Molluscum contagiosum	5	-	-		-
Pyogenic granuloma		8	-		-
Choristoma		1	-		-

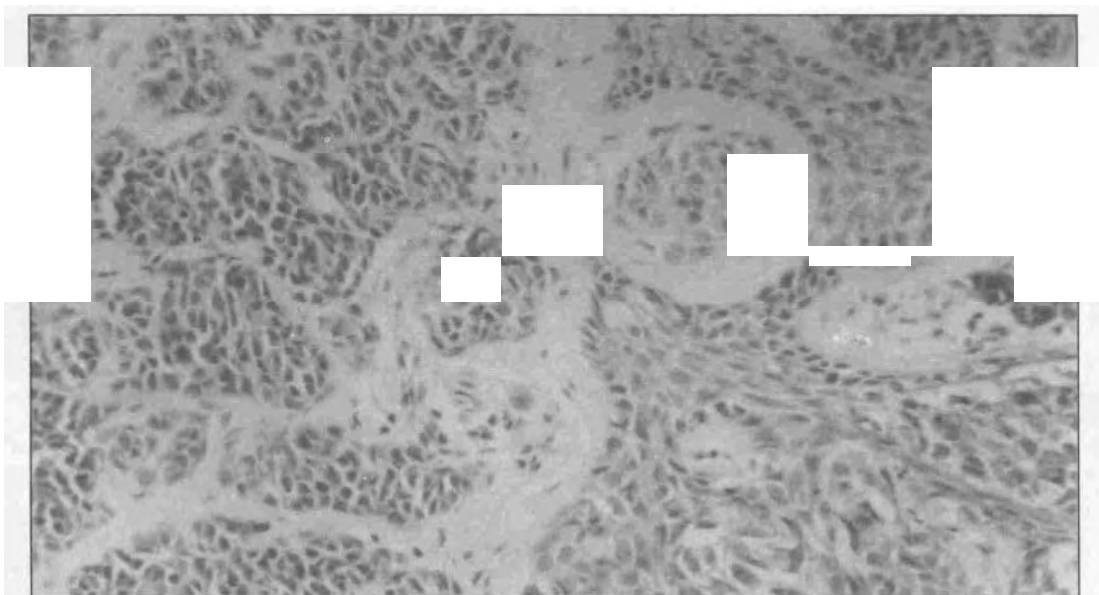


FIG. 1: Naevus cells in the dermis and epidermal junction which have abundant cytoplasm and large round nuclei with melanin pigment (H&E  $\times$  200).

*Lacrimal gland tumours* presented with the classical history of painless, slowly progressive proptosis of long duration in all the three cases. Histologically the two *pleomorphic adenomas* were made up of polyhedral to spindle shaped cells with oval nuclei, separated by myxoid and hyaline stroma. There were numerous duct-like structures containing eosinophilic secretions. The single case of *mucinous adenoma* histologically showed well-formed glandular structures lined by cuboidal to columnar epithelium and contained intraluminal mucin.

### **Malignant tumours**

**EyeLid:** One-fourth of the malignant tumours in the present study were from the eyelids (Table 2), and *basal cell carcinoma* was the most common malignant tumour of the lids. This tumour was seen in three elderly women of 44, 50 and 69 years of age. Two of them presented with small (5-8mm) ulcerated lesions in the skin of the lower lid near the inner canthus, and the third with a large (10 mm) cauliflower-like mass in the upper lid. Microscopically all the tumours were made up of cords of basaloid cells protruding downwards into the dermis and forming intertwining ramifications. Distinct palisading of the outer layer was visible (Fig.2). There was sparse mitosis and absence of pleomorphism. There was no recurrence of the tumour following excision and skin grafting in

any of the patients during the short follow-up period of six months. The single case of *squamous cell carcinoma* occurred in a 63-year-old woman as a small (6mm) nodular skin growth in the middle third of upper lid. Excision of the tumour and skin grafting was done. Histologically the tumour revealed typical nests of malignant squamous cells with the presence of intracellular keratinohyaline granules and concentric epithelial pearls (Fig.3). The tumour recurred after three years, infiltrating the tarsal plate. There was no regional lymphadenopathy. Excision of the recurrent tumour with reconstruction of the upper lid was done. There was no recurrence during the next four years of follow-up.

In the present series, a 35-year-old man presented with a small pigmented, smooth skin growth on the outer third of upper lid. The tumour was excised with a clinical diagnosis of naevus, but histology revealed *malignant melanoma* cells with large nuclei, prominent nucleoli, considerable pleomorphism and a high mitotic rate. The tumour cells contained brownish black pigment that was confirmed histochemically to be melanin. The tumour cells stained positively with S-100 and gave no reaction with cytokeratin or epithelial membrane antigen. The tumour did not recur during the five year follow-up period.

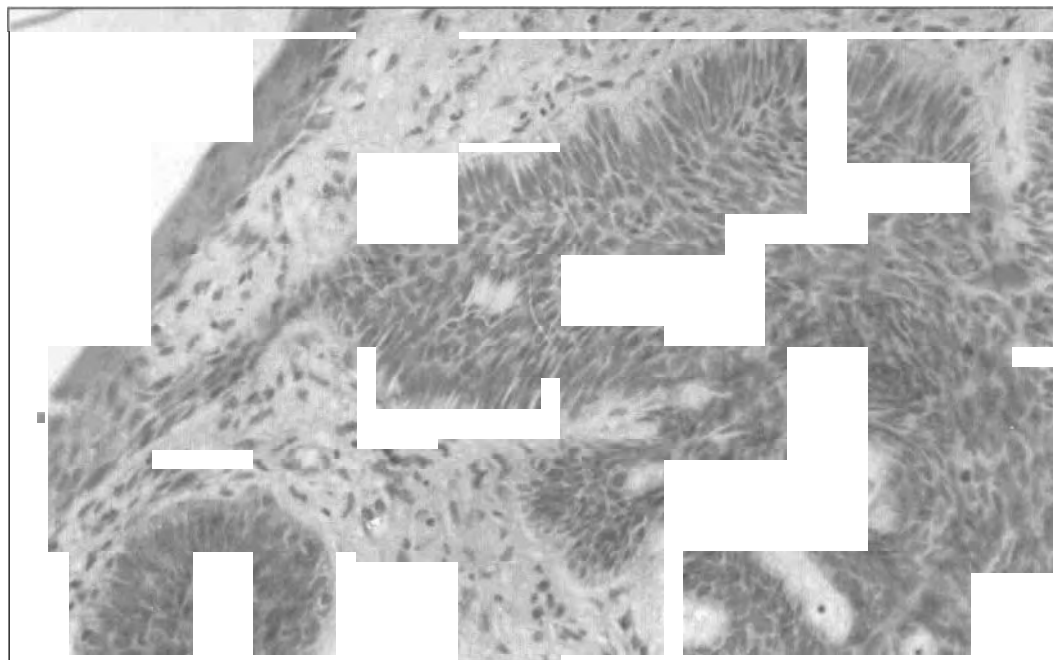


FIG. 2: Basaloid cells in the dermis forming intertwining ramifications with distinct palisading of outer layer (H&E  $\times$  200).

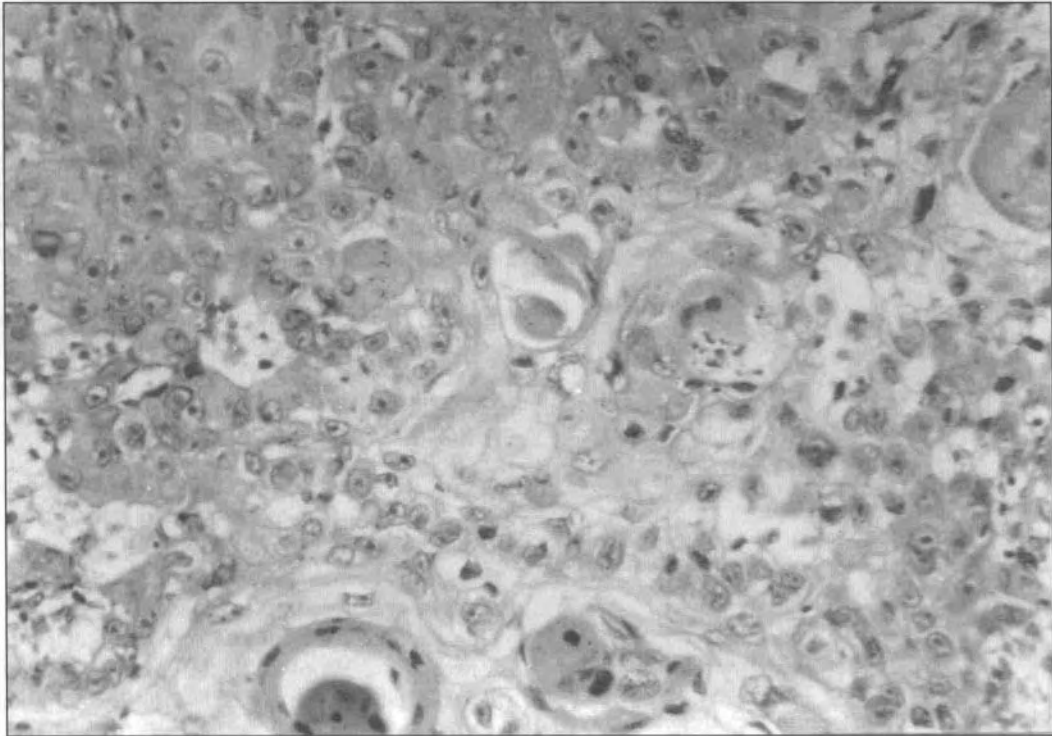


FIG. 3: Nests of malignant squamous cells showing intracellular keratin and epithelial pearls (H&E x 200).

**Conjunctiva:** Only 2 out of 28 conjunctival growths were found to be malignant in this study. The solitary *squamous cell carcinoma* was seen in a 73-year-old man as a small raised nodular lesion near the **limbus** on the temporal side. The tumour was excised. There was no infiltration into the deeper structures. The patient defaulted follow-up after one month.

A recurrent *malignant melanoma* of conjunctiva was observed in a 49-year-old woman as a large pigmented, nodular mass (25x20 mm) on the tarsal conjunctiva in the outer third of the left upper lid, with multiple small (5-8mm) pigmented lesions in the bulbar conjunctiva near the caruncle, upper punctum and at the 6 O' clock position near the **limbus**. All the tumour nodules were excised and confirmed by histopathological study. The tumour recurred near the upper punctum and in the bulbar conjunctiva after six months. There was no recurrence at the site of the main tumour in the upper tarsal conjunctiva. The recurrent lesions were excised and subjected to histological study. Three months later further recurrence of the tumour occurred at the lower **fornix** which was excised again. Since the vision was 6/6 in this eye throughout the course of the disease, enucleation was not done. There were no secondaries anywhere in the body. The patient

was referred for radiotherapy of the left eye.

**Retina:** Ten cases of *retinoblastoma* (6 in boys and 4 in girls) were seen in the present study. The mean age at presentation was 2.5 years with a range of 5 months to 4 years. The tumour was bilateral in 3 cases and unilateral in 7 cases (total 13 eyes). Leukocoria (white reflex in **pupillary** area), the most common mode of presentation, was seen in 8 eyes followed by leukocoria with proptosis in 3 eyes, leukocoria with squint in 1 eye and proptosis with a fungating mass in 1 eye. The disease was in an advanced stage in 3 cases with metastasis in the brain. Enucleation was done in all unilateral cases and in the more severely affected eye in bilateral cases. Histologically the tumour was made up of small monomorphic cells with hyperchromatic nuclei and scanty cytoplasm (Fig. 4). Six were well-differentiated with rosette formation, while four were poorly differentiated. Optic nerve involvement was seen in three cases (Fig 5). Children with evidence of metastasis and optic nerve involvement were given post operative radiotherapy and chemotherapy. The follow-up period ranged from 6 months to 4 years. There was no tumour recurrence in any of the patients. One child died at home after 6 months due to undetermined cause. Two children defaulted

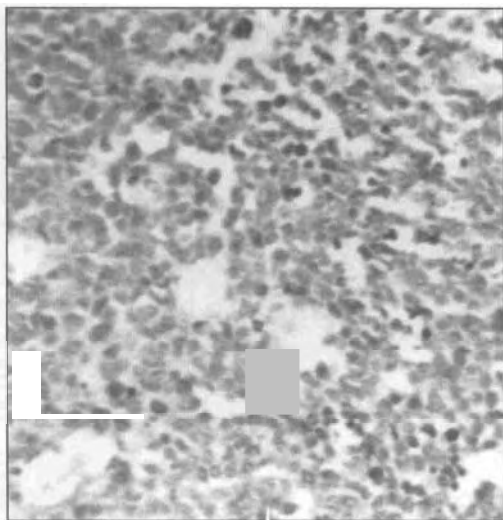


FIG. 4: Retinoblastoma showing sheets of monomorphic round cells with hyperchromatic nuclei and scanty cytoplasm (H&E × 200).

follow-up. Seven children are alive; 4 after one year, 2 after two years and 1 after four years of follow up. The last child developed delayed radiation cataract in the irradiated second eye. She regained useful vision after extracapsular cataract extraction with posterior chamber intraocular lens implantation in that eye. Calcification in the fundus was noted at the previous tumour site.

Orbit : Three malignant orbital tumours were seen in the present study and all of them presented as unilateral proptosis. *Non-Hodgkin's lymphoma* was seen in two males aged 46 and 69 years. Detailed investigations did not reveal any systemic disease. Histologically these tumours were made up of sheets of monomorphic large cells with scanty cytoplasm and prominent nucleoli. The tumour cells gave positive reaction with monoclonal B cell markers. The *meningioma* seen in a 50-year-old woman was an extension of the tumour from the sphenoid into the orbit.

**DISCUSSION**

A review of the histopathology register of the Pathology department, HUSM revealed that a total of 3952 tumours (2077 benign and 1875 malignant) were diagnosed from different regions of the body during the same period (1985-1993). Thus, ocular tumours and tumour-like lesions constituted 2.3% of all the tumours of the body (3.3% of all benign and 1.1% of all malignant tumours ). Gogi *et al*<sup>2</sup> studied 503 histopathologically proven **ocular** and adnexal tumours over a period of 25 years and reported that the orbit was the most common site (36.4%) followed by the eyelid (27.4%), conjunctiva (22.7%) and the eye ball (13.5%). However, in

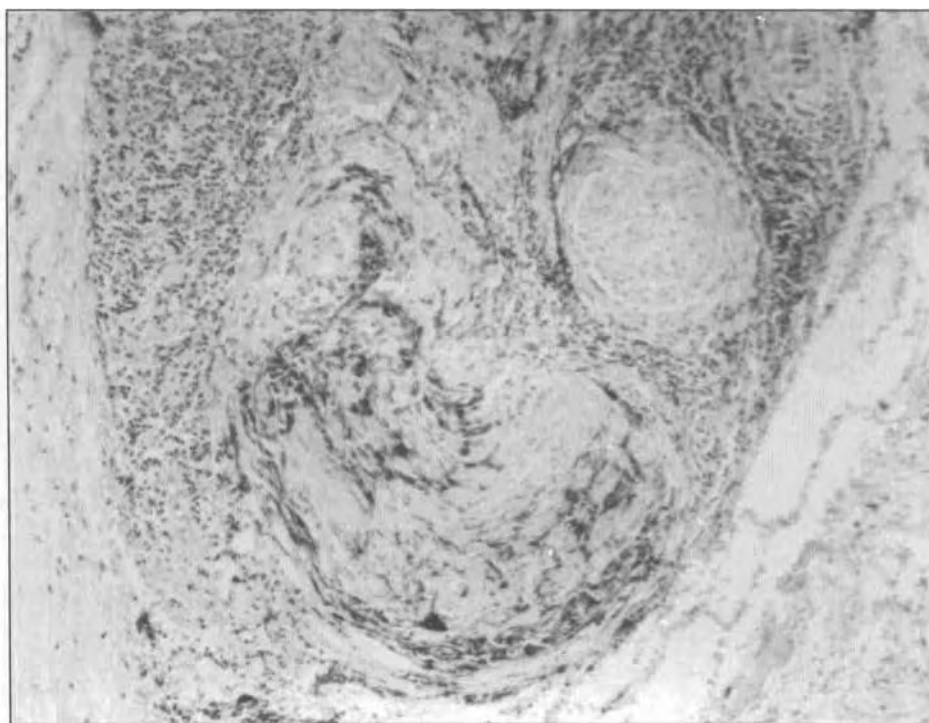


FIG. 5: Optic nerve is infiltrated by monochromatic round tumour cells of retinoblastoma (H&E × 200).

our present study growths in the eyelid constituted 51% of all cases, whereas the orbital tumours were the least frequent in occurrence.

Among the tumour-like lesions, dermoid cyst of the lids was the most common lesion (28.8%) and its incidence was much higher than that of 5.3% reported by Arora and Blodi.<sup>3</sup> Pyogenic granuloma was the most common (28.5%) tumour-like lesion of the conjunctiva. This lesion has been described to arise following chalazion operation and pterygium excision.<sup>4</sup>

Vaughan *et al*<sup>5</sup> stated that basal cell carcinoma is the most common malignant tumour of the eye lid (95%) and it usually involves the lower lid and inner canthus. However, Arora and Blodi,<sup>3</sup> in a study of 892 eyelid lesions, reported an occurrence of 19.3% basal cell carcinoma, 1.7% squamous cell carcinoma and 1.2% malignant melanoma. In the present study, we noticed a much lower prevalence of basal cell carcinoma (6.6%), and a slightly higher occurrence of squamous cell carcinoma (2.2%) and malignant melanoma (2.2%) in the eyelids. This could probably be due to the smaller number of cases in our study. Malignant melanoma constitutes approximately 1% of all the malignant neoplasms of eyelids.<sup>4</sup> Morphologically these are similar to melanomas elsewhere in the skin.

Malignant melanoma of conjunctiva is rare. It may arise from a pre-existing naevus, or from an area of acquired melanosis, or de novo from a normal appearing conjunctiva. Pigmentation may vary greatly and the clinical course is often unpredictable.<sup>5</sup> Only one case of conjunctival melanoma has been reported in the Malaysian literature.<sup>6</sup> In conjunctival melanoma, local excision is the treatment of choice, but a high recurrence rate (79%)<sup>7</sup> has been reported. In melanomas originating from precancerous melanosis, the recurrence has been reported to be 100%.<sup>8</sup> The risk of metastasis is high when the primary or a recurrent melanoma is located in the fornix, tarsal conjunctiva or caruncle. It is not always possible to be certain of the pathogenesis of recurrence in conjunctival melanoma. The recurrence could be due to multicentric lesions in patients with acquired melanosis showing widespread involvement of the conjunctiva, or due to local lymphatic spread of the tumour resulting in subepithelial satellite nodules subsequent to excision of the primary lesion, or a consequence of local contamination during surgery.<sup>4</sup> In the case reported in our study, pre-existing acquired conjunctival melanosis which was not clinically obvious, but was noted histologically in the conjunctiva

adjacent to the excised tumour could be a possible cause of recurrence.

Retinoblastoma is the most common intraocular malignant tumour in childhood, typically manifesting as leukocoria in the affected eye. Less common manifestations include strabismus, glaucoma, pseudohypopyon, hyphaema, vitreous haemorrhage, iris heterochromia, orbital cellulitis or severe intraocular inflammation simulating endophthalmitis.<sup>9</sup> In very advanced cases, a fungating mass presenting through a corneal perforation and proptosis caused by posterior orbital invasion via emissary vessels of the sclera are common clinical presentations.<sup>4</sup> In retinoblastoma patients, cellular differentiation and optic nerve involvement have prognostic importance in the survival of patients. Well-differentiated tumours are characterised by rosette formation. The mortality rate of patients whose tumours have abundant rosettes is about 8% and when combined with highly undifferentiated tumours it rises to about 40%. If the optic nerve is not involved, the mortality rate is only 8%; but if the tumour involves the lamina cribrosa, the mortality rate rises to about 15%. Optic nerve involvement beyond the point of surgical transection is associated with 65% mortality rate.<sup>10</sup>

In the present study, some of the problems encountered may relate to the late stage of the disease at the time of surgery. Occurrence of cancer in the eye in a young child was beyond the comprehension of some of the parents, and hence consent for removal of the eye was not readily available. Moreover, belief in traditional faith healers (bomohs) by some parents resulted in delayed acceptance of surgery. By the time the ineffectiveness of traditional treatment became apparent, the tumour had progressed to the stage of proptosis. Poor patient compliance and follow-up default were other problems in operated cases. Sukumaran<sup>11</sup> reported a similar experience in his study of 27 histopathologically diagnosed retinoblastomas over a period of twenty-three years in Kuala Lumpur. Leukocoria was also the most common (73.7%) mode of presentation in his study.

The present study indicates that a wide range of tumours and tumour-like lesions of the eye are encountered in Kelantan. Health educational campaigns are required to overcome the traditional barriers and will have a positive effect on the management and survival of patients. In general, early diagnosis and prompt surgical intervention followed by radiotherapy

and/or chemotherapy can result in either cure or good survival rates in ocular malignancies.

## REFERENCES

1. Zimmerman LE, Sobin LH. Histological typing of tumours of the eye and adnexa: International classification of tumours. No.24, Geneva : World Health Organisation, 1980.
2. Gogi R, Nath K, Leela A, Manoj S. Ocular and adnexal tumours. *Indian J Ophthal* 1979; 27: 25-7.
3. Arora AL, Blodi FC. Lesions of the eye lids- A clinicopathological study. *Survey of Ophthal* 1970; 15: 94-104.
4. Spenser WH. *Ophthalmic Pathology : An atlas and text book*. 3rd ed. Philadelphia: W B Saunders, 1985: Vol. 1, pp.156,218; Vol. 2, p.1314; Vol. 3, pp.2189, 2497, 2672.
5. Vaughan D, Asbury T, Riordan-Eva P. *General Ophthalmology*. 13th ed. New Jersey: Prentice Hall International , 1992: pp.86, 123.
6. Kandaiah R, Sukumaran K, Chandran S, Jayalakshmi P. Malignant conjunctival melanoma- A case report. *Med J Malaysia* 1988; 43: 178-80.
7. Brooks CJ. Conjunctival melanoma- Prognostic factors and analysis of a series. *Trans Amer Ophthal Soc* 1981; 78: 467-502.
8. Leisegnag TJ, Campbell RJ. Mayo clinic experience with conjunctival melanomas. *Arch Ophthal* 1980; 98: 1385-9.
9. Shields JA , Shields CL. Intra ocular tumours: A text and atlas. Philadelphia: W B Saunders, 1992: p.305-32.
10. Kanski JJ. *Clinical Ophthalmology : A systematic approach*. Oxford: Butterworth-Heinemann ltd , 1994 : p. 225.
11. Sukumaran K. Retinoblastoma - A 20 year review from University Hospital, Kuala Lumpur. *Med J Malaysia* 1991; 46: 129-35.