

REVIEW

Racial characteristics of human teeth with special emphasis on the Mongoloid dentition

Hashim Yaacob BDS, MSc, FDSRCPS, FDSRCS, *Phrabhakaran Narnbiar BDS, BSc Dent (Hons), MSc Dent. and **Murali D. K. Naidu BDS, M Med Sc.

*Department of Oral Pathology, Oral Medicine & Periodontology, Faculty of Dentistry, *Department of Oral Biology, Faculty of Dentistry and ** Department of Anatomy, Faculty of Medicine, University of Malaya, Kuala Lumpur, Malaysia*

Abstract

Determining the racial affinity of an unknown individual from dentition for identification is indeed a difficult endeavour. However, there are certain dental characteristics which are predominant in certain racial groups and these contribute important indicators in the identification process. Inherited dental characteristics are modified by prenatal and postnatal environmental and nutritional conditions. They can also become less discernible due to admixture of the various races.

Key words: Dental characteristics, Heredity, Mongoloids, Caucasoids, Australoids, Negroids.

INTRODUCTION

It is generally agreed by physical anthropologists, human biologists and geneticists that all men living today belong to a single species, *Homo sapiens*, and they therefore share a common ancestry. However, there exist today many different human groups and it is impossible to determine when and how these groups have developed different from each other. According to anthropologists, nature selects both the biological and cultural patterns of a population that are adaptive in a particular environment. These attributes contribute to the process of survival and reproduction of that group of population. Genetic alterations and environmental influences cause the individual variability within a population (polymorphic) or distinction between human groups (polytypic) which we refer as **rac**es.

Brues (quoted by Molnar¹) stated that a race is a division of a species which differs from other divisions by the frequency with which certain hereditary traits appear among its members. Among these traits are features of external appearance that make it possible to recognise members of different population by visual inspection with greater or less accuracy. Members of such a division share ancestry with one another to a greater degree than they share it with individuals of other races. Finally races are usually associated with a particular geographic area.

HEREDITY AND RACIAL CHARACTERISTICS

The major racial groups of the world are broadly classified as Caucasoids, Mongoloids, Negroids and Australoids (Australian aborigines). In Peninsular Malaya there are three major ethnic groups namely, Malays, Chinese and Indians. The Ibans and Bidayus are natives of Sarawak while Kadazans and Dusuns belong to Sabah. Apart from Indians who belong to the sub-group of Caucasoid called Indo-Dravidian (Indo-European), all the others belong to the Mongoloid race.

It must be emphasised that it is impossible to specify any distinct **anatomic** characteristic exclusively to a particular race, but careful examination of physical, skeletal and dental structures may collectively support the racial identity of an individual. The present criteria of racial classification are phenotypic in nature. The distinguishing characteristics in the study of races are: (1) skin, (2) hair, (3) head form, (4) face form, (5) nose, (6) eyes, (7) stature, and (8) dentition. However, racial characteristics should be considered as only suggestive and not specific diagnostic features in determining the racial origin of the individual.

The recognition of inherited racial characteristics is essential in forensic investigation for determining identification. Heredity is the process of transmission from one generation to its

offspring, genetic factors that determine individual characteristics. Consequently the origin and variations of certain dental characteristics have become useful as descriptive or inferential evidence in forensic work. Teeth, although prone to caries during a person's lifetime, exhibit excellent postmortem preservation. This relative indestructibility provides an important factor in the identification process. However, heritability of racial characteristics are also conditioned by developmental and environmental agents in the growth process. Studies² on tooth size variability in Yuendumu Australian Aborigines have indicated that genetic factors account for approximately 60% of tooth size variability in both deciduous and permanent dentitions, while 40% of observed phenotypic variability is contributed by environmental alterations. This includes the maternal status which affects tooth germ initiation and subsequent development. Garn *et al*³ have reported that prolonged gestation, large size at birth and high birth weight were found to be associated with larger teeth, as were maternal hypothyroidism and maternal diabetes. In contrast, short gestation, lower birth weight and length and maternal hypertension were associated with reduced tooth dimensions. Researchers have also reported reduction in tooth size and alteration in groove and cusp morphology with increasing fluoride level in experimental studies with rats. This may indicate an important role for fluoride or other trace elements on tooth morphology development.⁴

Dental traits or characteristics⁵ are features such as ridges, bulges, cusps, grooves, pits, junctions and relationships that occur in different parts of the crowns or roots of the teeth which vary in size, range and dimension. Teeth are excellent and reliable sources of information and the expressivity of certain features may indicate a positive or negative relationship of a person to a particular racial group. According to Dahlberg⁶ the following *dento-anthropologic* structures are useful for identification purposes and ascertaining racial affinities:

- cusp size, number and location
- occlusal groove patterns
- root systems
- number and arrangement of teeth
- individual tooth measurement
- dimensional proportions between different teeth (e.g. 1st molar: 2nd premolar)
- occlusal and bony relationship
- nature of pulp chamber and canal
- microscopic tooth-surface characteristics

Methods of quantification

Teeth are one part of the skeleton for which measurements on the living after eruption are directly comparable with the fossil remains which have survived ravages of time.' Both metric and non-metric parameters can be ascertained. To establish metric parameters measurements are taken and this is sometimes referred as odontometry. Here the mesiodistal, buccolingual, crown height etc. are taken using digital calipers. 'Scoring' or qualitatively describing characteristics such as presence / absence of a trait, degree of its expression and frequency (unilateral or bilateral) may have to be carefully done. Any subjective bias must be avoided and the parameters employed must be exacting and reproducible.

When certain trait/character occur in small percentages amongst the population, then it becomes an abnormal trait. However if the percentage is much higher, then the trait is just a variation. Variability in the dentition results from genetic and environmental influences acting on developing teeth, jaws and other craniofacial structures. The environmental influences are nutrition, hormonal activity and postnatal functional modifications. Malformations may arise if growth in the jaws and other craniofacial elements is not coordinated. Space within growing jaw may sometimes have to be competed for. Ultimately this causes different combinations of tooth size and shape within or between populations to occur.⁸

Mongoloid

The racial differences are more marked in the permanent dentition than the deciduous dentition. The most striking feature in the Mongoloid dentition is found on the lingual surface of the incisors. There is the accentuation of the lateral or marginal ridges which are fused with a raised cingulum and creates a deep lingual fossa. The ridge fades towards the incisal edge and this gives the tooth a 'shovel' or 'scoop' shape (Figs.1&2). This condition is found in approximately 90% of Mongoloids inclusive of Eskimos and American Indians.⁶ Occasionally, there may be a groove on the lingual surface at the cervical margin extending onto the root and "spur like or finger" like projections from the cingulum towards the incisal margins? Frequently the prominent lingual marginal ridges which produce the Mongoloid shovel-shaped incisor extends on to the labial surface. These produce a mesiodistal concavity of the labial surface and

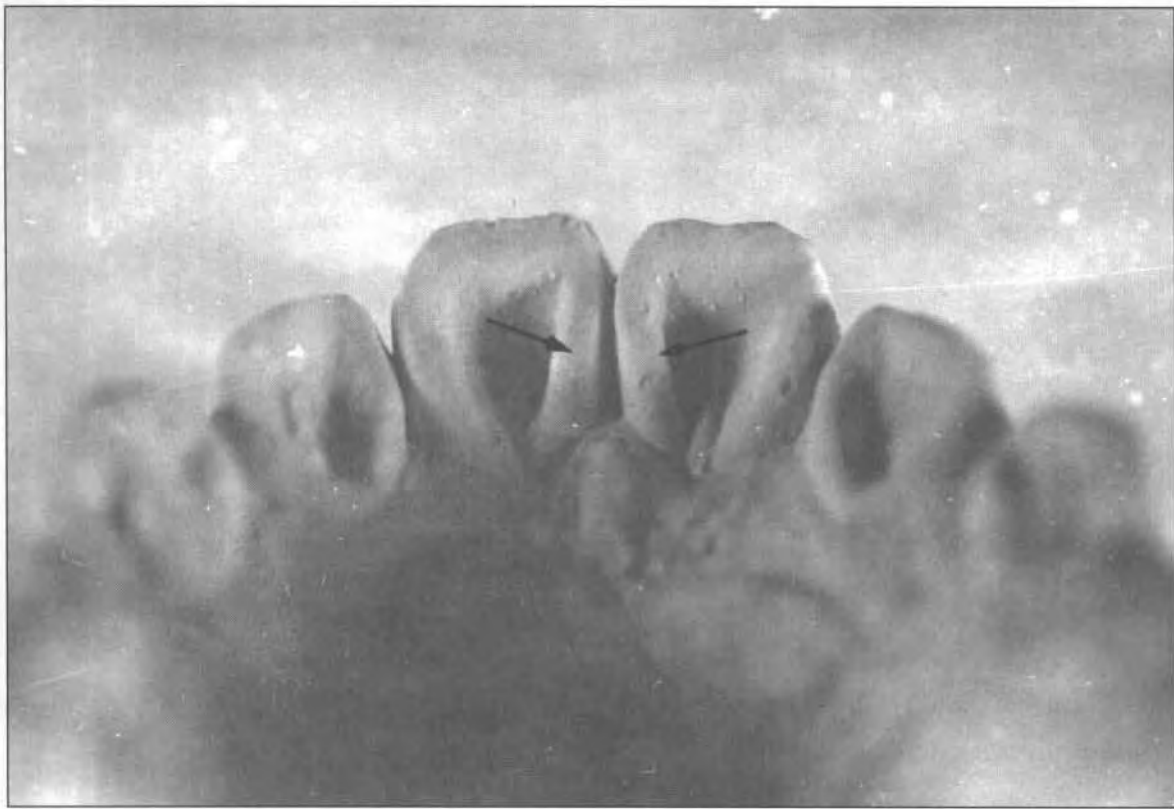

FIG. 1: Prominent marginal lingual ridges (upper incisors).

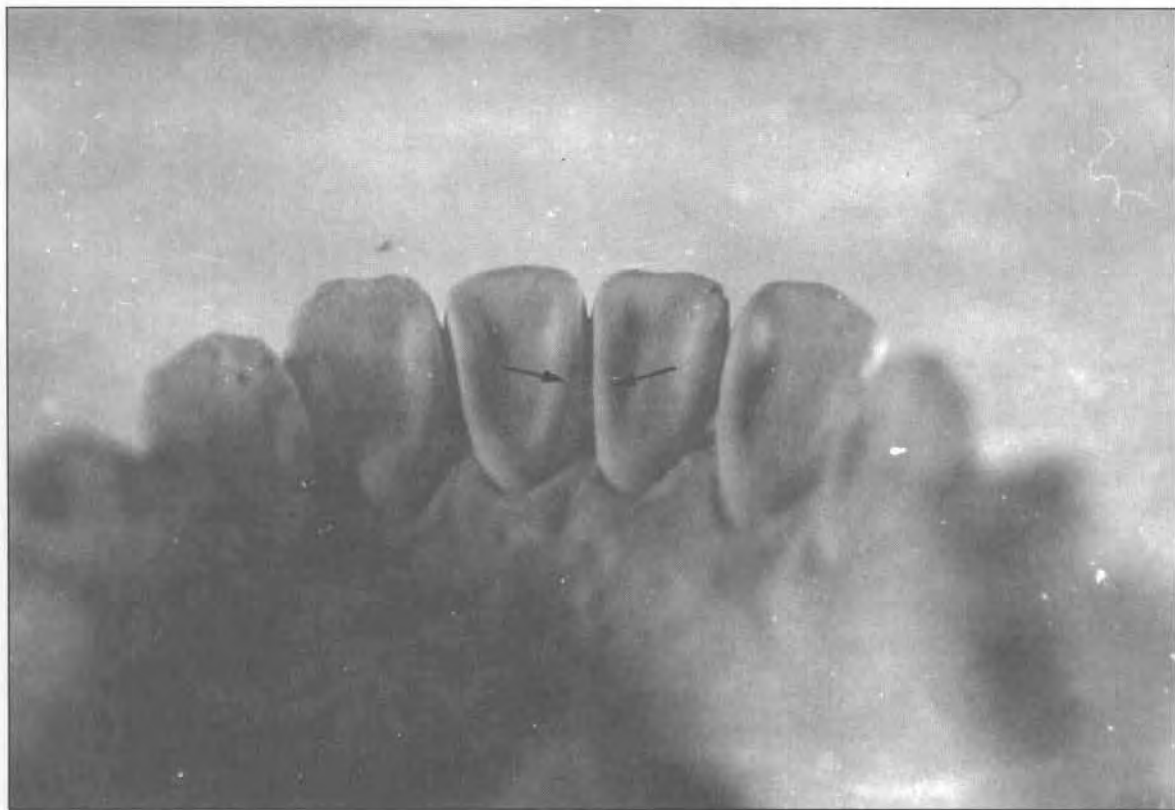


FIG. 2: Prominent marginal lingual ridges (lower incisors).

are termed "double-shovel shaped" incisor (Fig. 3).^{10,11,12} Furthermore, the maximum width of the Mongoloid crown of the anteriors when observed is located further away from the incisal edge when compared with Caucasoids.

Bailit¹³ has shown that the population of Asian ancestry have large upper lateral incisors relative to the size of central incisors. This was demonstrated amongst the Japanese where the central incisors in male on the average were only 19% bigger than the lateral incisors. In contrast the values for American Whites and Norwegian Lapps were 33% and 24% respectively. In a similar study by Yaacob & Talib¹⁴ amongst Malay adolescents, it was found that the central incisors were bigger mesiodistally only by 17% than the lateral incisors of the males and were bigger by 13% in the females. These findings were in agreement with the Mongoloid values of Bailit. The upper lateral incisor is also sometimes affected by reduction, thereby assuming a barrel shape and looking like a bicuspid.⁶

Owing to flattened nasal bones, the upper alveolus seems to be inclined violently forward (apparent prognathism) in order to carry the upper incisors sufficiently labially to occlude in front of the lower incisors. The roots of the upper

incisors therefore, incline forward and the crowns turn at an angle - otherwise the incisal edges would be pointing forward and protruding between the lips. From the lateral view, Mongoloid incisors therefore show a greater curvature than the Caucasoid. This angulation is also observed with the canines.¹⁰

The premolar of Mongoloids may display a tubercle, usually on the buccal cusp. This tooth is known severally as Leong's premolar or Oriental premolar and this condition is scientifically termed as Den's Evaginatus. Fracture of this tubercle (which has an extension of the pulp) will cause infection of the tooth and endodontic treatment will have to be instituted.

The 1st and 3rd Mongoloid molar maybe larger than 2nd although the general trend is progressive decrease in size before backwards? Presence of the third molar may sometimes exhibit a five-cusped tooth and 43% of second molars examined amongst Singaporean Chinese exhibited bilateral five cusp forms.¹⁵ This is in contradiction to much dental literature which describes this tooth as having four cusps and having a squarish occlusal surface. In the lower molars, the distal (5th) cusp is usually more lingually placed than Caucasoids. Root size and

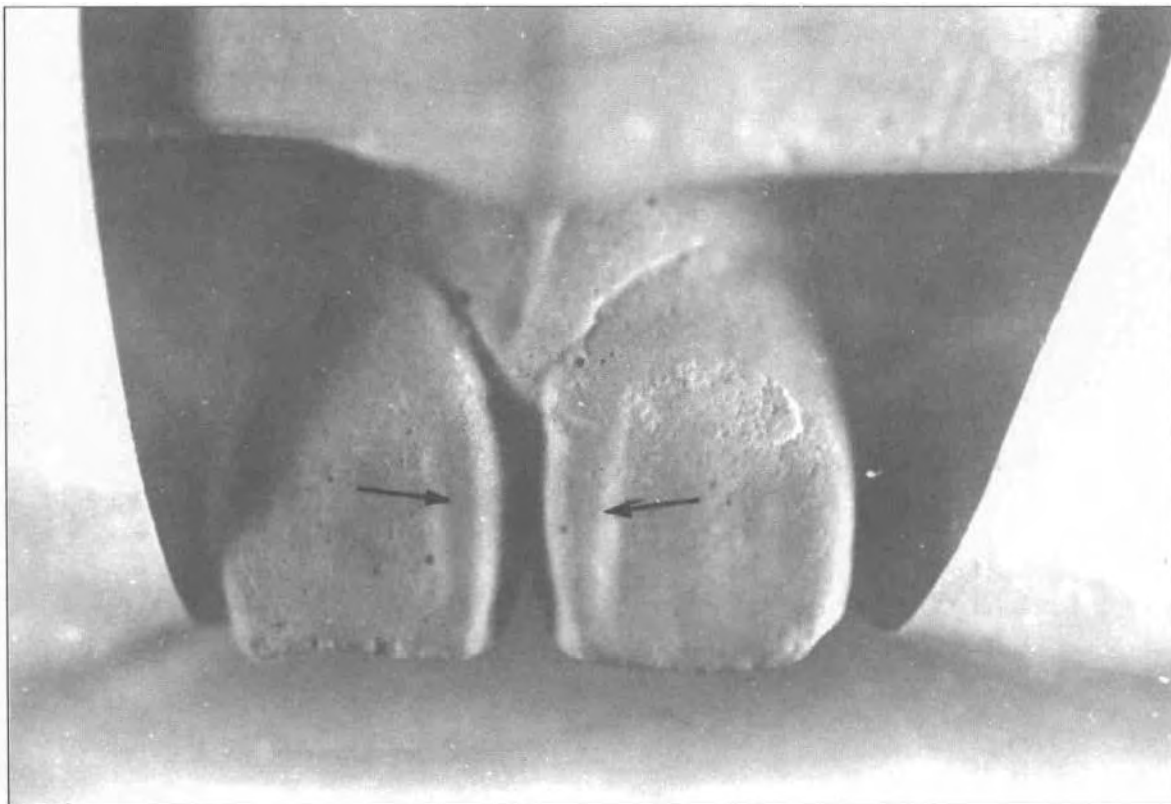


FIG. 3: Prominent labial marginal ridges (upper incisors).

length reduces posteriorly and sometimes with an additional distolingual root in the lower first and third molar. This is also observed in second deciduous molar. In a study¹⁶ of extracted mandibular molars amongst Singaporean Chinese, disto-lingual roots were exhibited in 7.9 % of the first molars and 3.7% of the third molars extracted. None was found in the second molars. In an earlier study¹⁶ in 1971 on the first mandibular molars of Keewatin Eskimos, the incidence was much higher at 19%. In general the anatomical roots of Mongoloids are shorter but the root trunks better developed. Taurodontism, caused due to increased growth of root trunk is also observed in Mongoloids. Complete taurodontism is only detected in maxillary 1st molars whereas the other molars may exhibit partial taurodontism.⁹

Furthermore in Mongoloids, the enamel extends below the general contour of the enamel border; sometimes between the bifurcation of the roots. It is more frequently detected in the mandibular molars when compared with maxillary molars and more so on the buccal surface. 79% of extracted first mandibular molars of Hong Kong Chinese demonstrated this feature with a large percentage having extension to the furcation entrance." There may also be the presence of protostylid cusp which is on the buccal surfaces of the mesiobuccal cusps of the lower permanent molars and lower 2nd deciduous molar. Apart as cusp it may vary as a pit, slight

eminence or produce a deviated buccal groove.⁵ Enamel pearls, which are protuberances at the external radicular portion of a tooth are reasonably low in occurrence with a predilection for the third maxillary molars.¹⁸ The absence of cusp of Carabelli is another notable feature in this race. If present, it is usually a reduced form. Sofaer¹⁹ has further reported that 30% of the Japanese population have missing third molars.

In general, Mongoloids have a parabolic arch with large incisors, canines, small premolars and large molars behind them. This is emphasized as a rule especially in the lower arch."

Caucasoid

Caucasoids usually have narrow 'v' shaped arch giving rise to crowding of teeth.¹⁰ The anterior teeth of Caucasoids are described as 'chisel-shaped' and are generally smaller and have smoother lingual surface. The cusp of Carabelli is another noted feature which is common amongst 37% of the Caucasoids.²⁰ This is seen on the mesio-palatal cusp of the maxillary first permanent molars and the maxillary second deciduous molars. Apart from cusps this trait may vary as pits, furrows or slight protuberances.^{5,21} The second molars have usually four cusps as opposed to five in some races. This was observed in 94% of Anglo-saxons examined by Lavelle.²² Moreover it is even commented that there is greater frequency of bent and splayed

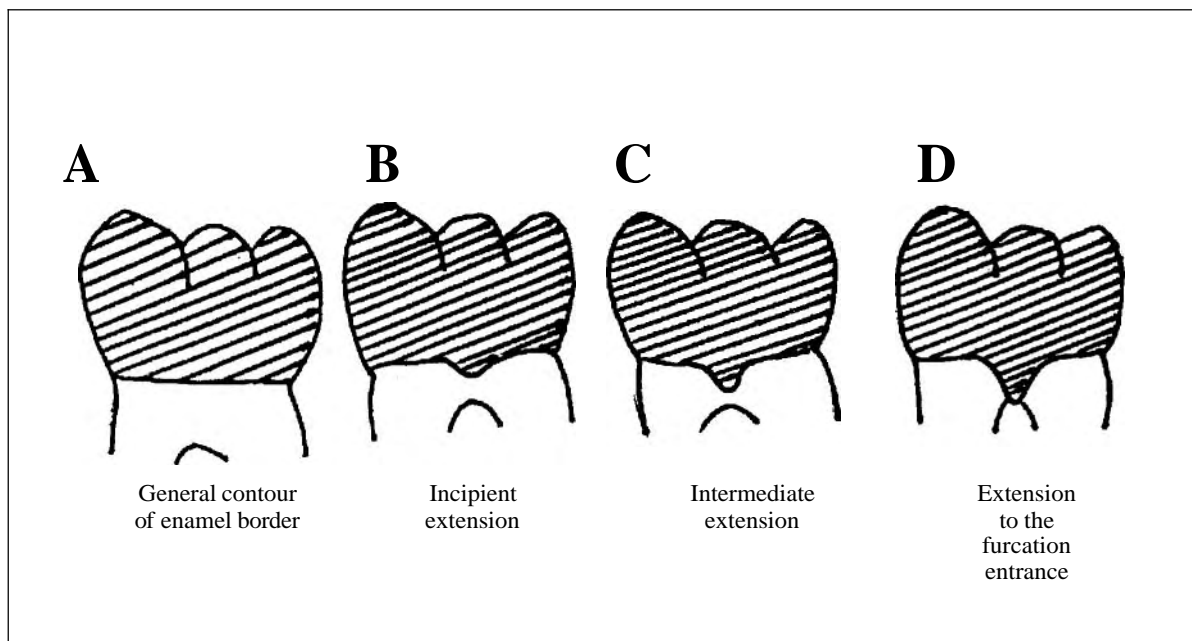


FIG. 4: Various types of enamel extension.

roots in all molars examined in this race.

Some Central Europeans have a wide based prominent cingulum on the lingual surface of their incisors rather than the rolled smooth continuum common to most Europeans. The upper lateral incisor is the more variable of this type and the reduced lateral incisor forms are usually **peg-shaped**.⁶ Shovel shaped incisors is exhibited amongst in about 30-36% of the Danish and Swedish populations, 46% of the Palestinian Arabs and also in 51% of the **Indians**.²³ According to **Lunt**¹¹ it is the maxillary lateral incisors of Europeans that are more likely to appear as shovel shaped.

Australoid

The dental arch of the **Australoids** which is large, naturally accommodates larger sized teeth. They have the largest molars amongst any living race (termed as megadont). The mesiodistal diameter of the first molar is 10% longer than that found in Norwegian Lapps and White **Americans**.^{13,24} Presence of large premolars is also noted but the anteriors are relatively small in comparison. **Midline diastema** is usually therefore present. They live on hard gritty food and exhibit gross attrition on the incisal and occlusal surface of their teeth. Sand and ash is sometimes accidentally incorporated during preparation of the food, giving it an abrasive quality. It causes a reduction of incisogingival length of teeth resulting in 'spatulate' teeth. Lack of intercuspitation of teeth results in a typical edge to edge relationship. Another aspect of attrition concerns the plane of occlusion of the teeth. When the upper and lower first molar erupts, the buccolingual plane of occlusion is oblique with the level higher buccally and lower lingually. With attrition the plane of occlusion in the molar region assumes an opposite angle of obliquity to its original angle.²⁵ **Meisal drift** of teeth is another notable feature caused due proximal attrition. This is caused due to wear of contacting proximal surfaces resulting in reduction in the mesiodistal crown size.¹² **Shovel shaped incisors and the appearance of cusp of Carabelli** are rare. According to **Campbell**,²⁶ there may be the presence of enamel pearls exhibited between the roots and the third molars may be missing.

Negroid

The teeth of negroids are small with spacing (especially **midline diastema**). There is a increased tendency for the existence of supernumerary teeth. The lower first premolar has two distinct

cusps; sometimes even three cusps. The presence of the cusp of Carabelli and shovel shaped incisor is uncommon. The third molars are always present and rarely impacted.

CONCLUSION

Teeth are the most mineralized and hardest structure in the human body. The study of their origin and the variations is called dental anthropology. This area of study is useful in archaeology, paleontology, physical anthropology and forensic pathology/dentistry. Its application is also important in clinical dentistry as deep pits and grooves between cusps become the focus for the initiation and progression of caries. In summary, the final tooth form observed in a person's jaw represents the sum total of the effects of inherited genetic control; the developmental process including interaction between neighbouring teeth; and also the prenatal and postnatal environmental influences. Variations can therefore occur during initiation of tooth germs, their growth, organic matrix apposition and subsequent mineralization.¹⁸

Heredity certainly plays a large part in the development of dental characteristics of an individual. Determining the racial affinity from teeth is certainly not an easy matter, but it is often the most useful step in the identification process of an unknown body. Some of these characteristics are judged subjectively while others may have to be expressed in terms of measurements and indices. Caution must be exercised, however, in concluding the racial identity of an individual from teeth as a specific skull may lack certain traits or may exhibit contradictory ones. Furthermore, hybridization between races in a cosmopolitan population has caused much blending or breakdown of these traits causing racial determination from dental characteristics increasingly arduous.

ACKNOWLEDGEMENTS

Sincere thanks to Ms. Karen Lam (4th. year dental student) for allowing impressions of her teeth to be taken.

REFERENCES

1. Molnar S. Human variation, race, types and ethnic groups (2nd. ed). New Jersey: Prentice-Hall, 1983.
2. Townsend GC, Brown T. Heritability of permanent tooth size. Am J Phys Anthropol 1978; 49: 497-50
3. Garn SM, Osbome RH, Alvesalo L, Horowitz SL. Maternal and gestational influences on deciduous and permanent tooth size. J Dent Res 1980; 59: 142-

- 3.
4. Townsend GC. Anthropological aspects of dental morphology with special reference to tropical population. In: **Prabhu SR, Wilson DF, Daftary DK & Johnson NW** (eds.) Oral diseases in the tropics. Oxford: Oxford University Press, 1992: 45-58.
5. Dahlberg AA. Ontogeny and dental genetics in forensic problems. *For Sci Int* 1985; 30: 163-76.
6. Dahlberg AA. Dental traits as identification tools. *Dent Prog* 1963; 3: 155-60.
7. Brace LC. Australian tooth-size **clines** and the death of a stereotype. *Curr Anthropol* 1980; 21: 141-64.
8. Brown T. Developmental aspects of occlusion. *Ann Aust Coll Dent Surgeons* 1969; 2: 61-7.
9. Low T, Goh SW. The dentition of Malaysians of various racial origin. The morphology of the human dentition. Faculty of Dentistry, University of Malaya 1972: 129-41
10. Aitchison J. Some racial contrasts in teeth and dental arches. *Dent Mag Oral Topics* 1965; 82: 201-5.
11. Lunt DA. Identification and tooth morphology. *Int J For Den* 1974; 2: 3-8.
12. Aitchison J. Some racial differences in human skulls and jaws. *Br Dent J* 1964; 116: 25-33.
13. Bailit HL. Dental variation among populations - An anthropologic view symposium on **genetics**. *Dent Clin North Am* 1975; 19: 125-39.
14. Yaacob H, Talib R. Mesiodistal dimensions of teeth of Malay adolescents. *Hosp Dent* 1993; 5: 39-41.
15. Loh HS. Mongoloid features in the permanent mandibular second molar in Singaporean Chinese. *Aust Dent J* 1991; 442-4.
16. Loh HS. Incidence and features of three-rooted permanent mandibular molars. *Aust Dent J* 1990 ; 35: 434-7.
17. Zee KY, Chiu MLB, Holmgren CJ, Walker RT, Corbet EF. Cervical enamel projections in Chinese first permanent molars. *Aust Dent J* 1991; 36: 356-60.
18. Loh HS. A local study on enamel pearls. *Sing Dent J* 1980; 5: 55-9.
19. Sofaer JA. Genetic variation and tooth development. *Br Med Bull* 1975; 31: 107-10.
20. Krogman WM, Iscan MY. The human skeleton in forensic **medicine**. (2nd edition). Springfield: Charles C Thomas, 1986.
21. Rusmah M. The cusp of Carabelli in Malaysians. *Trop Dent J* 1992; 15: 13-5.
22. Lavelle CLB. Mandibular molar configurations in different racial groups. *J Dent Res* 1971; 50:1353.
23. Haines DH. Racial characteristics in forensic dentistry. *Med Sci Law* 1972; 12: 131-8.
24. Dahlberg AA. The changing dentition of man. *J Am Dent Assoc* 1945;32: 676-90.
25. Pounder DJ. Forensic aspects of aboriginal skeletal remains in Australia. *Am J Forensic Med Pathol* 1984; 5: 41-51.
26. Campbell TD. Dentition and palate of the Australian Aborigine. Adelaide: **Hassel** Press:1925.