

## Massive small bowel infarction and duodenal perforation due to abdominal polyarteritis nodosa: a case report

Myint TUN, MMedSc (Surgery), FRCS (Edin.) and AK MALIK\*, MD (Path), MNAMS (India).

Departments of Surgery and \*Pathology, Faculty of Medicine, University of Malaya, Kuala Lumpur.

### Abstract

A 37-year-old Chinese male presented with an acute abdomen. Surgical exploration revealed duodenal perforation, extensive small bowel infarction and peritonitis. Histopathology of the resected bowel showed characteristic features of classic polyarteritis nodosa. The latter also involved mesenteric arteries in the form of tiny aneurysms. Steroids could not be started due to: (i) overwhelming microbial infections and (ii) fear of more perforations in other areas of the bowel. Such a presentation of polyarteritis nodosa is uncommon. Its recognition prior to surgery, management and prognosis is discussed.

*Key words:* Small bowel infarction, duodenal perforation, polyarteritis nodosa.

### INTRODUCTION

Polyarteritis nodosa (PAN) usually presents with multisystem involvement.<sup>1</sup> The stomach and intestine are involved in 30-50% of those affected.<sup>2</sup> Gastrointestinal symptoms and signs occur in two-thirds of patients.<sup>1</sup> Uncommonly, gangrene or perforation of the bowel due to necrotising vasculitis with occlusion of the regional vessels is encountered.<sup>2</sup> We report a case with extensive small bowel infarction.

### CASE REPORT

#### *Clinical features*

A 37-year-old Chinese male presented with a 2 week history of epigastric pain, aches and weakness in the lower limbs. He also noticed the passing of tea-coloured urine for 4 days. For the last one year he had been suffering from asthmatic attacks for which bronchodilators and inhalants were prescribed. There was no history suggestive of peptic ulcer. Oesophagogastro-duodenoscopy in a private hospital revealed mainly inflamed antrum and duodenum but no overt ulceration. He was put on H<sub>2</sub> antagonists and Omeprazole with no relief of symptoms. On admission he was febrile and jaundiced. The pulse was 74/minute and the blood pressure 160/100 mmHg.

The abdomen felt soft and slightly tender. A provisional diagnosis of gastritis/duodenitis and acute intermittent porphyria was made and he was treated conservatively.

#### *Investigations*

Haemoglobin was 11.5 g/dl, total leucocyte count  $27.6 \times 10^9/l$  with a differential count of polymorphs 82%, lymphocytes 3%, eosinophils 9%, monocytes 5% and metamyelocyte 1% and a platelet count of  $492 \times 10^9/l$ . The ESR was 35 mm in the first hour. Urine routine examination was normal. Blood for Hepatitis B surface antigen (HBsAg) and urine for porphyrins tested negative. Total serum proteins was 57 g/l and serum albumin 12 g/l. The serum bilirubin level was 135  $\mu\text{mol/l}$ , AST 52 IU/l, ALT 58 IU/l, and alkaline phosphatase 210 IU/l. The blood urea level was 26.7 mmol/l, serum creatinine 191  $\mu\text{mol/l}$ . Serum electrolytes and amylase levels were normal. Plain X-ray of abdomen was normal. Ultrasound showed mild homogenous hepatomegaly.

#### *Clinical course*

The abdominal pain and fever persisted and on the 7th post-admission day, the patient developed abdominal rigidity and guarding. He was referred to the surgeon as the general condition deteriorated rapidly. Emergency laparotomy revealed a 1 cm perforation in the first part of duodenum, severe generalized peritonitis, and patches of gangrene involving the distal jejunum and proximal ileum. Suture and omentoplasty of the duodenal perforation, resection of the middle 2/3rd of the small bowel and peritoneal toilet were performed. The mesentery did not show any haemorrhage. There were no apparent nodules seen in the vessels. The major vessels

felt **pulsatile**. The stomach, large bowel, liver and spleen on inspection looked normal.

Postoperatively, the patient deteriorated progressively, developed acute renal failure and disseminated intravascular coagulation **preterminally**. He had superadded polymicrobial infections with *Acinetobacter* and *Klebsiella pneumoniae* grown from the incision wound, **peritoneal** fluid and tip of the central venous catheter. **In spite** of antibiotics and a supportive regimen, the patient died on the 13th postoperative day. In view of overwhelming microbial infection, steroids had not been administered. Full autopsy was refused but needle biopsies to the liver, kidney and lungs were consented to.

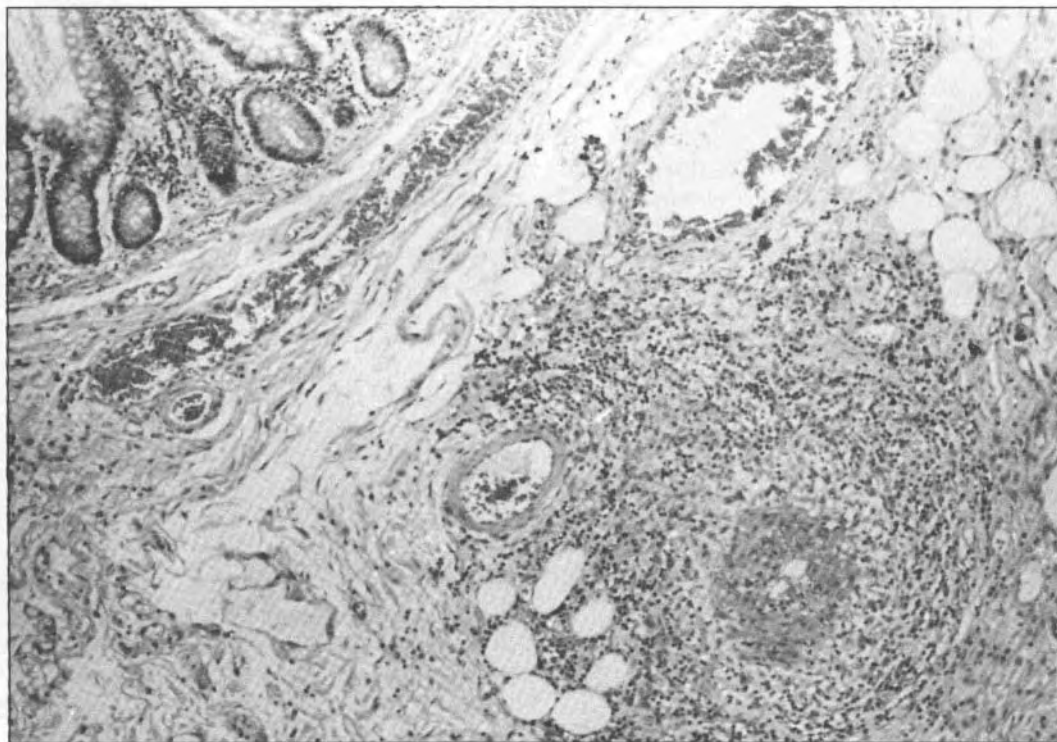
### *Histopathology*

Grossly, the segment of resected small bowel measured 115 **cms** in length. Externally, it appeared dark with a diffuse greyish brown exudate on the serosal aspect. On opening, multiple transverse ulcerations (varying in size from 0.5 to 3.0 cm diameter) covered with greenish exudate were noted. The mesenteric vessels felt bead-like and showed tiny nodular bulgings especially at the bifurcations. Microscopically, the ileal segments showed

patchy ischaemic ulcerations and **transmural** necrosis. Besides vascular ectasia and congestion, medium sized submucosal arteries (Fig.1) showed endothelial proliferation, occasional **luminal** thrombi, distinct fibrinoid necrosis in the media, focal to patchy destruction of internal elastic lamina, sparse giant cell reaction and a varying proportion of chronic inflammatory cells mainly eosinophils, infiltrating the adventitia (Fig.2). Occasional extra- and intravascular granulomas were also observed. In small arteries, there was evidence of healing in the form of recanalized thrombi or fibrous occlusion of the lumina. Eosinophils in the muscularis propria and patchy to diffuse serosal exudate were also observed. The veins were conspicuously not involved by this necrotising inflammation (Fig.3). Similar pathology was seen involving the branches of mesenteric arterial arcades producing distinct aneurysms. Thus, a pathological diagnosis of ischaemic infarction due to polyarteritis nodosa (PAN) was made. Biopsy of the liver, kidney and lungs did not reveal any features of vasculitis.

### **DISCUSSION**

PAN was first described in 1866 by **Kussmaul** and **Maier**.<sup>1</sup> The basic pathological changes in



**FIG.1:** Photomicrograph showing fibrinoid necrosis and luminal occlusion affecting a small submucosal artery. Note the perivascular granulomatous inflammation. (H&E X 25).

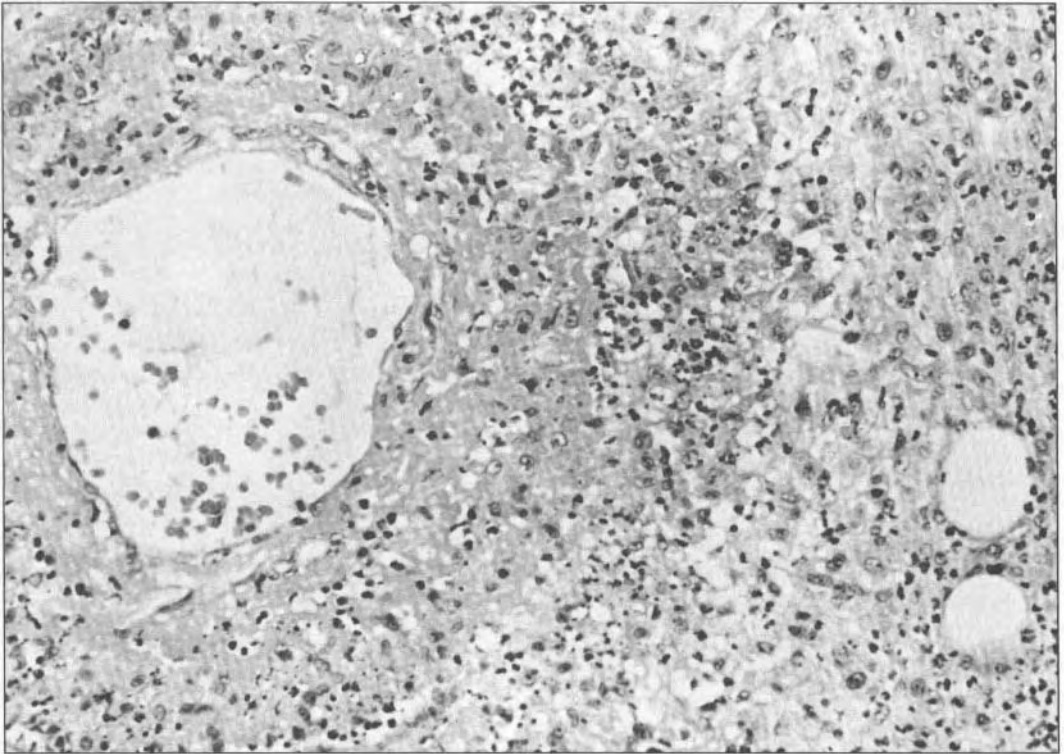


FIG. 2: Photomicrograph showing a vessel with acutely inflamed media, fibrinoid necrosis and perivascular granulomatous inflammation rich in eosinophils. (H&E X125)

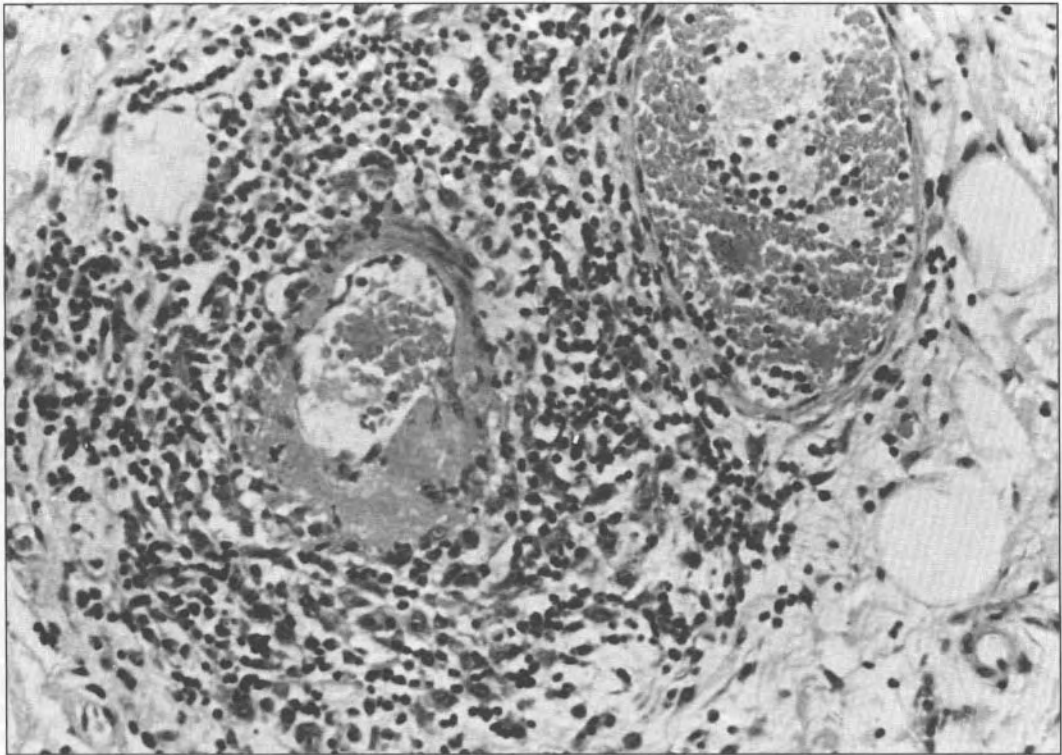


FIG. 3: Photomicrograph showing distinct fibrinoid necrosis and periarteriolar eosinophil infiltration sparing the venule. (H&E X125).

PAN consist of acute inflammation and fibrinoid necrosis of small and medium sized muscular arteries affecting multiple organ systems throughout the whole body. It affects predominantly young adult males. Originally all vasculitis were thought to be of classic PAN type. However, it became apparent that disseminated systemic vasculitides were a broad group of disorders with different manifestations.<sup>4</sup>

Histopathologically, PAN is akin to chronic serum sickness with deposition of antigen and antibody complexes in the vessel wall. Acute inflammatory necrosis of tunica intima and media leads to fragmentation of vessel wall, luminal narrowing, thrombosis, weakening and aneurysm formation or rupture.

Gastrointestinal involvement in PAN is a common cause of morbidity and mortality. This patient illustrates the uncommon but serious complications of duodenal perforation and small bowel infarction. In PAN, gastrointestinal involvement is noted in 30-50% of cases.<sup>2,4</sup> In our case the first indication of the disease was evident on histology. These unusual catastrophic manifestations of infarction, bowel necrosis and haemorrhage carry a mortality of 75 to 100%.<sup>5</sup> Our patient presented with abdominal pain which is common in two thirds of cases with PAN.<sup>6,7</sup> Aneurysm formation and rupture may result in massive gastrointestinal haemorrhage.<sup>6</sup> Gut infarction is reported in 10% of patients with PAN.<sup>7</sup>

Early diagnosis of PAN with gastrointestinal involvement is difficult. Eosinophilia is present in 25% of cases.<sup>2</sup> Muscle biopsy yields poor diagnostic result.<sup>8</sup> Liver or omental biopsy at macroscopically negative laparotomy is positive in half the cases.<sup>6</sup> Liver, mesenteric and renal angiograms can pick up saccular aneurysms and arterial narrowing in 60% of cases.<sup>1</sup>

Acquisition of tissue for histological diagnosis is essential. Once PAN is established, joint medical and surgical management is essential to prevent the relapse and complications such as perforation, haemorrhage or obstruction. In severe cases bowel rest, decompression via nasogastric suction and/or total parenteral nutrition should be started early. Antibiotics may be essential to treat polymicrobial infections. Prognosis of untreated patients has been improved by use of steroids with 48% survival at 5 years.<sup>9</sup> The combination of cyclophosphamide with prednisolone results in 96% remission.<sup>1</sup>

## ACKNOWLEDGEMENTS

Grateful thanks are due to Professor A.M. Aljafri, Head of Department of Surgery, University of Malaya for permission to publish this report, Mrs Helen Kok for typing of the manuscript and Mr. M.Y. Lim for photographic assistance.

## REFERENCES

1. Kussmaul A, Maier R. Periarthritis Nodosa. *Dtsch Arch Klin Med* 1866; 1: 484-517.
2. Nightingale E. The gastroenterological aspects of polyarteritis nodosa. *Am J Gastroenterol* 1959; 31: 152-65.
3. Travers RL. Polyarteritis nodosa and related disorders. *Br J Hosp Med* 1979; 7: 38-45.
4. Fauci AS, Haynes BF, Katz, P. The spectrum of vasculitis. Clinical pathologic, immunologic and therapeutic considerations. *Ann Intern Med* 1978; 89: 660-76.
5. William HE, Martin RS, Edwards WH, Mulherin JL. Surviving gastrointestinal infarction due to polyarteritis nodosa: A rare event. *Am Surgeon* 1992; 58: 167-72.
6. McCauley RL, Johnston MR, Fauci AS. Surgical aspects of systemic necrotising vasculitis. *Surgery* 1985; 1: 104-10.
7. Wold L, Baggenstoss A. Gastrointestinal lesions of polyarteritis nodosa. *Mayo Clinic Proc* 1949; 24: 28-35.
8. Maxiener SR, McDonald JR, Kirklin JW. Muscle biopsy in the diagnosis of periarthritis nodosa, an evaluation. *Surg Clin North Am* 1952; August 1225-33.
9. Fronhert PP, Sheps SG. Longterm follow-up of periarthritis nodosa. *Am J Med* 1967; 43: 8-14.