

BENIGN ORBITAL NEURILEMMOMA — AN UNCOMMON CAUSE OF UNILATERAL PROPTOSIS

SC PEH MBBS MPath*

AND

OV RAMANI MBBS**

Summary

The occurrence of neurilemmoma in general is not infrequent, but it is a relatively uncommon orbital neoplasm. Proptosis caused by the tumour may be mistaken for Grave's disease. This report presents two female patients, aged 42 years and 30 years, with progressive unilateral proptosis. The former patient was investigated for Grave's disease prior to discovery of an orbital neurilemmoma mimicking exophthalmos. Both patients recovered after surgical removal of the neurilemmomas.

INTRODUCTION

Orbital neurilemmoma is a relatively uncommon neoplasm. It has been estimated to account for only about 1.5%¹ of orbital tumours. In the ten year period from 1971 to 1980, only two cases of orbital neurilemmoma were biopsied in the University Hospital, Kuala Lumpur, constituting 2.4% of orbital tumours seen in this hospital. Their features are described below.

CASE REPORTS

Case 1

A 42 year old Chinese woman was seen at the University Hospital, Kuala Lumpur on June 18, 1970 for progressive proptosis of the left eye over the past four months. She was extensively investigated and a clinical diagnosis of euthyroid ophthalmic Grave's disease with unilateral proptosis was made. However 2 months later, examination showed, in addition to proptosis, the presence of a left superior orbital tumour with downward displacement of the eye-ball. The tumour was soft, cystic and non-pulsatile. Movements of the eye-ball were full and vision was 6/6. Surgical removal of the orbital tumour was advised. However, the patient absconded but returned six months later with similar complaints. The tumour had remained almost the same size with no additional signs or symptoms. The encapsulated tumour was then removed en mass under general anaesthesia.

Pathology: The tumour was a solid encapsulated mass measuring 3 cm x 1.5 cm x 0.5 cm. Histological examination showed it to be a

neurilemmoma. It was composed of nodules of spindle-shaped cells which exhibited nuclear pallasading and a fibrillar matrix. In areas, the stroma had a loose reticular appearance.

Case 2

A 30 year old Malay woman presented with a two year history of progressive bulging of the left eye. Three months earlier, she had also noticed an orbital swelling at the superior medial aspect of the eye. There was no pain or diminishing visual acuity. The eye-ball was displaced downwards and outwards, but movements were full. The intraorbital tension was normal. The orbital swelling was cystic, non-pulsatile and irreducible. General examination did not reveal any cafe-au-lait spots. The orbital mass was removed in toto under general anaesthesia. Post-operative recovery was uneventful and the proptosis improved.

Pathology: The tumour removed was a well-encapsulated yellowish cystic mass. Histological sections showed a neurilemmoma with areas of cystic degeneration and two distinct patterns of arrangement. The Antoni type A pattern (Fig. 1) consisted of compactly arranged spindle cells arranged in wavy flowing cords or whorled bundles and exhibited nuclear pallasading, while the Antoni type B pattern (Fig. 2) showed round and oval cells in a loose reticular stroma.

DISCUSSION

Neurilemmoma, also known as Neurolemmoma, Schwann-cell tumour or Schwannoma, is a benign, encapsulated tumour arising from the neuro-

* Lecturer. Department of Pathology, University Hospital, Kuala Lumpur (Address for reprint requests).
** Medical Officer. Department of Ophthalmology, University Hospital, Kuala Lumpur.

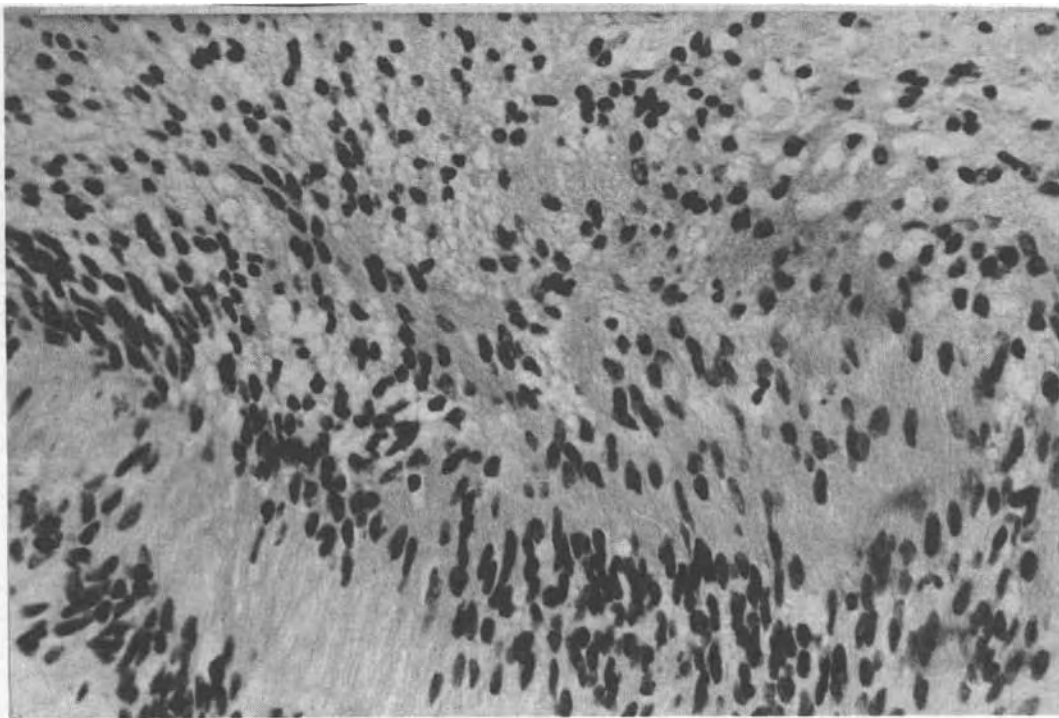


Fig. 1: Antoni type A pattern: nuclear pallasading and fibrillar matrix. H & E x 300.

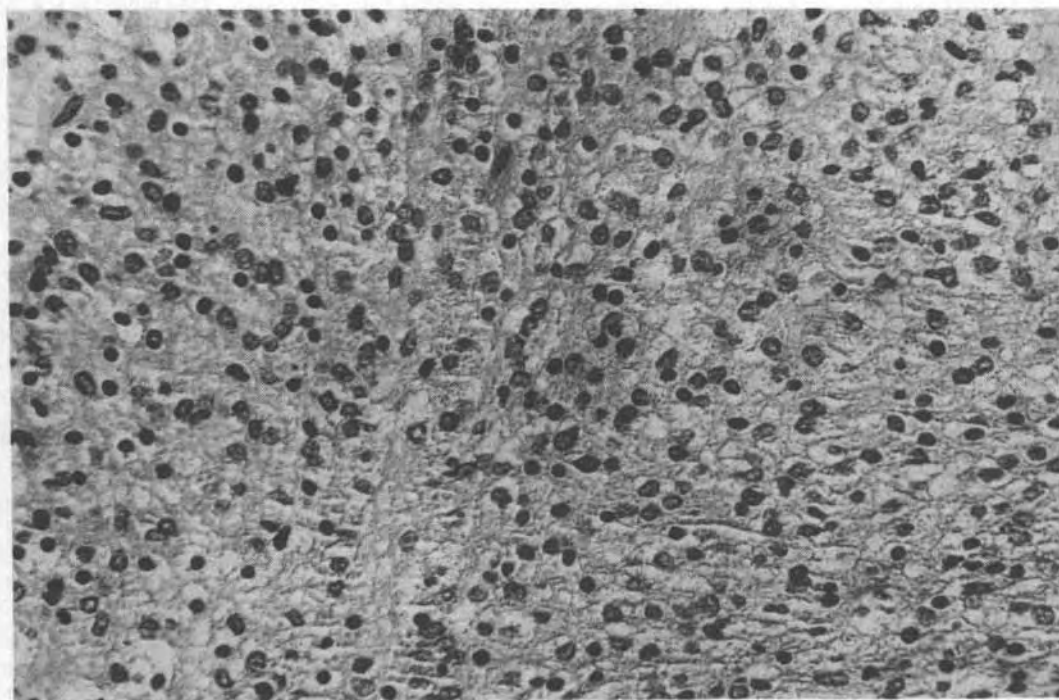


Fig. 2: Antoni type B pattern: round and oval cells in loose reticular stroma. H & E x 300.

ectodermal sheath of Schwann and occurs in subjects of all ages without predilection for either sex² or any ethnic group.³ However, a small proportion of cases are associated with von Recklinghausen's neurofibromatosis.² The tumour can arise from any peripheral, autonomic or cranial nerve, with the exception of the optic and olfactory nerves, since these do not have Schwann cells.³ For this reason, it is uncommonly seen in the orbit. Henderson and Reese estimated the incidence of orbital neurilemmomas to be approximately 1.5%^{1,4} of orbital neoplasms. Most orbital neurilemmomas are believed to arise from the oculomotor nerve because it is widely distributed in the orbit. Sensory changes are absent, as would be expected if the **trigeminal** nerve is involved.

As it is an uncommon orbital tumour, proptosis caused by an orbital neurilemmoma may be mistaken for Grave's disease, and it is not surprising that our first patient was extensively investigated along those lines. Grave's disease was found to be the most common cause of asymmetric proptosis by Schutz, Richards and Hamilton, and Hugh MacMillan Moss.⁵ Hugh MacMillan Moss also noted in his study that the commonest orbital tumour causing unilateral proptosis was hemangioma. In his study of 230 cases of unilateral expanding lesions of the orbit, he found only two neurilemmomas.

A neurilemmoma is attached to and occupies an eccentric position in relation to its nerve of origin, which may not be identifiable at the time of surgery. In the orbit, as in most other sites, it may be a round, ovoid, fusiform or occasionally bosselated growth. The cut surface is usually pinkish grey and may show irregular yellow areas and cysts, surrounded by a fibrous capsule. The tumour tissue characteristically exhibits two contrasting tissue patterns, designated as Antoni type A and B. The type A pattern is compact with its spindle cells arranged in wavy, flowing, interlacing cords or whorled bundles. The long oval nuclei are characteristically orientated as in pallasades (the nuclear rows of Verocay), wherein they exhibit a polar disposition. The type B pattern is composed of cells that are widely separated and haphazardly disposed in a loose reticular stroma. There is no

nuclear pallasading or fibrillar regimentation in the type B pattern.

Orbital neurilemmomas are usually solitary⁴ and generally grow slowly. The usual presenting symptoms are exophthalmos, sometimes blurring of vision and impaired mobility of the eye-ball. A long interval between the onset of proptosis and surgical removal is common. In both our patients, the duration of symptoms prior to diagnosis were one and two years respectively. Tumours in the posterior quadrant of the orbit cause patients to seek treatment earlier due to associated blurring of vision resulting from compression of the optic nerve.¹ The superior quadrant is the commonest site for the tumour. This was true in both our patients and the affected eyes were displaced downwards. Neurilemmoma is essentially a benign lesion which rarely undergoes malignant transformation.⁶ Recurrence usually follows incomplete removal of the initial tumour whereas complete excision carries an excellent prognosis.

ACKNOWLEDGEMENT

We wish to thank Dr. LM. Looi for her advice and encouragement.

REFERENCES

1. Henderson JW. Orbital tumors. Philadelphia: WB Saunders, 1973.
2. Ashley DJB. Evans' histological appearances of tumors. 3rd ed. Edinburgh: Churchill Livingstone, 1978.
3. Harkin JC, Reed RJ. Solitary benign nerve sheath tumors. In: Firminger HI, ed. Tumours of the peripheral nervous system. Washington, D.C: Armed Forces Institute of Pathology, 1969: 29-51.
4. Reese AB. Tumors of the eye. 2nd ed. New York: Harper and Row, 1963.
5. Moss HM. Expanding lesions of the orbit. A clinical study of 230 consecutive cases. Am J Ophthalmol 1962; 54: 761-70.
6. Schatz H. Benign orbital neurilemmoma. Sarcomatous transformation in von Recklinghausen's disease. Arch Ophthalmol 1971; 86: 268-73.