

## PSEUDOTUMOURS IN HAEMOPHILIA - A REPORT OF TWO CASES

CG LOPEZ DCP, FRCPA\*

AND

N THANALETCHIMY MBBS\*\*

### Summary

A case of pseudotumour of the left ankle in a twenty year old Malay with severe Haemophilia A, who defaulted treatment for one year, and another in the left gluteal region in a thirty eight year old Chinese with severe Haemophilia A are reported. Both cases which developed complications of pseudotumours, demonstrate the importance of early and adequate treatment of muscle bleeds in haemophiliacs.

### INTRODUCTION

Pseudotumour formation is a rare but serious aftermath of haemorrhage in haemophiliacs, being potentially life threatening. The term pseudotumour describes a progressive cystic swelling involving muscles, produced by recurrent haemorrhage and accompanied by radiographic evidence of bone involvement.' Radiological changes consist of areas of bone destruction and new bone formation as well as calcification or ossification of surrounding soft tissue or both. The clinical picture may be indistinguishable from that of a malignant bone tumour. The entity was first reported in 1918 by Starker.<sup>2</sup> A review of literature by Jensen and Putman<sup>3</sup> showed 61 reported cases of pseudotumours. Fifteen surgically treated cases were also reported between 1959 and 1968. Because of the rarity of this entity, few doctors have experience in diagnosing and managing it.<sup>4</sup> Both cases reported here had to be referred to the Haemophilia Reference Centre in Cardiff.

### Case Reports:

Case 1 - Z.Z., a twenty year old severe haemophiliac with FVIII level of less than 1%. presented in May 1976 with a painful swelling of the left ankle. Infusion with cryoprecipitate to

raise the FVIII:C level to 35% together with analgesics, relieved the pain. After an absence of one year he was admitted to hospital on two occasions in 1978 with pain and persistent swelling of the left ankle and was similarly treated with relief. On 10.1.79 he was admitted with a large mass of the left ankle measuring 12 cm by 18 cm and spontaneous bleeding from two superficial ulcer sites on the dorsal surface of the mass (Fig. 1). X-ray of the left ankle showed a soft tissue swelling involving bone. The periosteum was elevated and there was bone destruction with new bone formation giving rise to a 'soapbubble' appearance (Fig. 2). The leg was immobilised by a plaster of Paris cast and the wound dressed daily. Cryoprecipitate to raise the level of FVIII:C to 35 to 40% was infused daily. In spite of treatment, two sinuses which oozed blood and sero-sanguinous fluid developed in early March. Enterobacteria was cultured from the fluid on 2.4.79. The haemoglobin dropped to 7.6 gm% and a mild jaundice developed on 25.4.79. By this period 745 bags of cryoprecipitate and 930 units of FVIII:C had been transfused. The pseudotumour was increasing in size and he became febrile. He was referred to the Haemophilia Reference Centre at Cardiff on 6.7.79.

\* Director, National Blood Transfusion Centre, General Hospital, Kuala Lumpur.

\*\*Medical Officer, presently attached to the Department of Pathology, Faculty of Medicine, University of Malaya, Kuala Lumpur (Address for reprint requests).

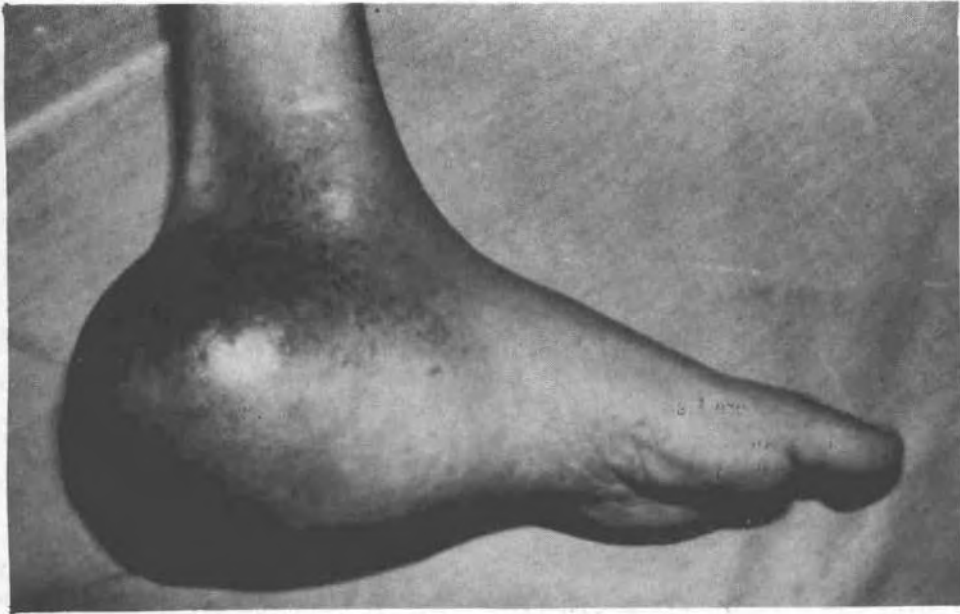

Fig. 1: Case 1: Lateral view of mass over left ankle.

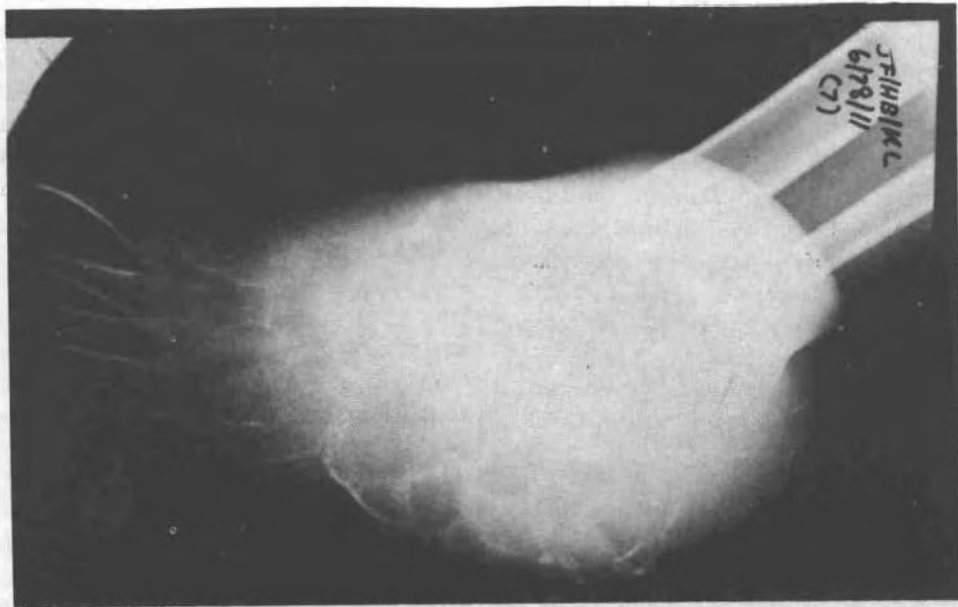


Fig. 2: Case 1: Lateral radiograph of left ankle showing "soap bubble" appearance and soft tissue mass.

Investigations done at the Haemophilia Reference Centre at Cardiff showed a growth of *Pseudomonas* cultured from the sinus fluid. Serum bilirubin was 56 mmol/L (normal average 0–17) and haemoglobin was 9.7 gm/dl with a reticulocyte count of 7%. HBsAg was negative but anti-HBs, anti-HBc, and anti-HA were positive. The *Pseudomonas* infection was controlled with intravenous injection of carbenicillin and gentamicin together with cryoprecipitate. The haemoglobin was raised to 14 gm/dl with blood transfusions. To reduce intravascular haemolysis due to isoagglutinins, ABO compatible cryoprecipitate was given throughout his hospital stay.

On 15.5.79 the pseudotumour, which at operation was seen to have destroyed the calcaneum and the tarsal bones, was completely excised and a compression bandage applied under general anaesthesia. FVIII:C level was maintained at 95–110% with infusions of commercial FVIII:C concentrates. From the fourth post-operative day cryoprecipitate was infused to maintain the FVIII:C levels at 60–80%. On the seventh post-operative day, on 22.5.79, a haematoma was evacuated from the foot under general anaesthesia. Recurrence of the haematoma necessitated another evacuation on 12.6.79 and deep tension sutures were applied through the foot. The wound was re-dressed on 26.6.79, 7.7.79 and 31.7.79. He made an uneventful post-operative recovery. Three months after the operation the wound had completely healed and he was able to move about with specially fitted surgical boots and elbow crutches.

Case 2 – L.L.K., a 38 year old severe haemophilic with a factor VIII level of less than 1% presented on 16.3.78 with a history of a large cystic, somewhat painful mass over the left gluteal region. He observed that the swelling developed gradually after an intramuscular injection which he had received several years previously. The mass over the left gluteal region was about 18 cm in diameter, cystic and tender (Figs. 3,4). X-ray of the pelvis showed a large soft tissue shadow lateral to the left hip and ileum (Fig. 5). No bony changes were seen. The pain was relieved with bed rest and cryoprecipitate infusion to raise the FVIII level to 35%.

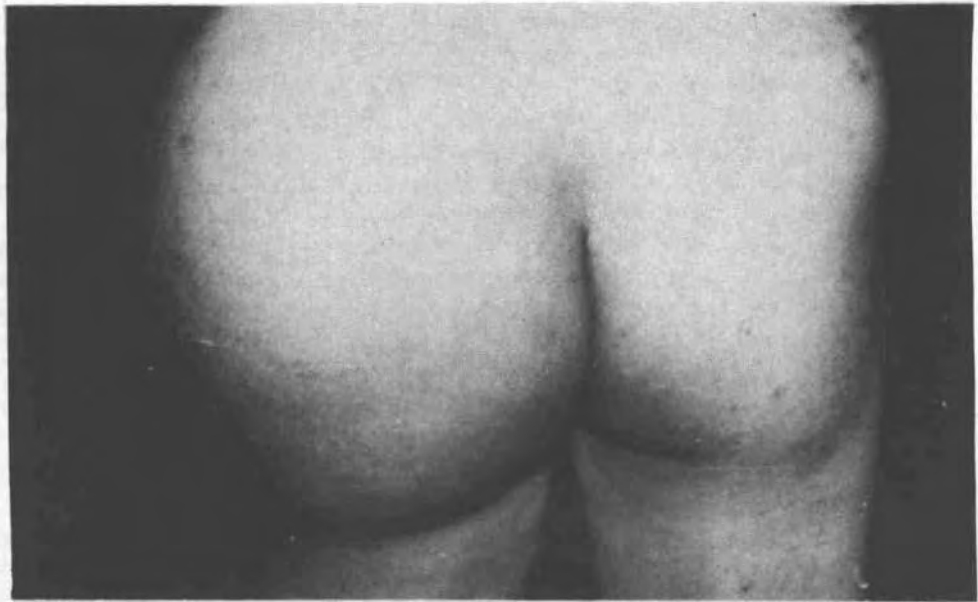
When seen again on 27.9.79 the swelling had increased in size and was painful. Examination revealed that the mass had increased to 20 cm in diameter. The patient was admitted, confined to bed and infused daily with cryoprecipitate to maintain levels of FVIII at 35%–40%.

Between 29.9.79 and 24.1.80 he was infused with a total of 491 bags of cryoprecipitate and 3580 units of Factor VIII concentration. Despite treatment, two sinuses appeared followed by a transient erythematous rash associated with fever. The sinuses oozed bloody fluid periodically. The patient was referred to the Haemophilia Reference Centre in Cardiff for surgery on 25.1.80.

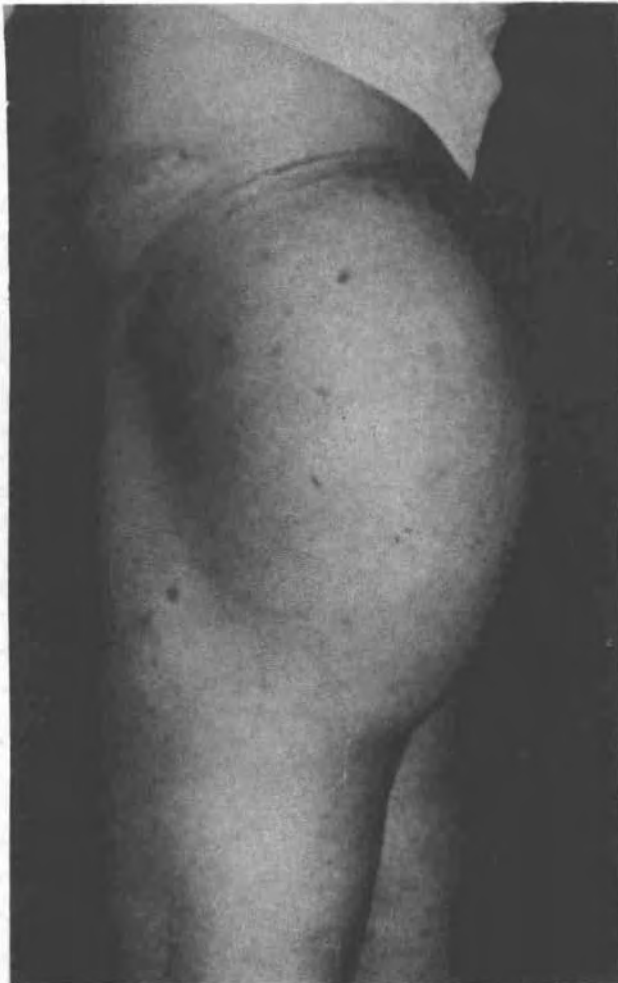Investigations carried out at the Cardiff Haemophilia Centre showed a raised aspartate transaminase level, although other liver function tests were within normal limits. Tests were negative for HBsAg but positive for anti-HBs and anti-HBc. Swab of the sinus discharge grew *Staph aureus* and treatment with clotrimazole was commenced. Cryoprecipitate was infused to maintain a continuous level of FVIII:C at 20–30%.

This treatment reduced the redness and tenderness of the pseudotumour as well as the pyrexia. The pseudotumour and cyst wall were completely excised on 6.2.80, under commercial FVIII:C cover of 3000 units.

Post-operatively trough levels of Factor VIII:C were maintained at 50–70% by twice daily infusions of approximately 2000 units of commercial Factor VIII concentrate. This was continued until the sixth post-operative day when it was changed to twenty-five packs of cryoprecipitate twice daily to maintain the same level. On the tenth post-operative day, he bled into the operation site in spite of adequate Factor VIII:C levels. At the second operation the wound was re-opened under cover of 2000 units of FVIII:C, and 950 mls of clot were extracted and drains inserted. Post-operatively the trough level of FVIII:C was maintained at about 90% with infusions of 25 packs of cryoprecipitate twice daily. A total of twenty seven units of blood was used between the two operations. He developed jaundice and his red cells became Coomb's positive to a titre of 1/64. The drains were removed under FVIII:C cover after



**Fig. 3: Case 2: Mass in left gluteal region.**



**Fig. 4: Case 2: Lateral view of mass in left gluteal region.**

two weeks. On the third post-operative week replacement therapy was reduced to 20 packs of cryoprecipitate twice daily. Gentle physiotherapy and isometric exercises were begun. On the fifth post-operative week cryoprecipitate infusion was reduced to 12 packs twice daily. Regular physiotherapy followed and at the time of discharge, on the seventh post-operative week, he could walk with the aid of crutches.

He returned to Kuala Lumpur on 30.3.80 and was admitted to hospital for management of the surgical wound which had not healed. A sinus measuring 4 mm by 9 mm discharged altered blood (Fig. 6). The wound turned septic and surgical debridement was carried out on 17.4.80. Post-operatively, dressing was carried out daily under cover of 5 bags of cryoprecipitate (500 iu of FVIII:C). He was discharged on 8.6.80, after the wound had completely healed.

## DISCUSSION

Pseudotumour is seen only in 1% of severe haemophiliacs.<sup>5</sup> The aetiology is unknown. The pseudotumour appears to form in three stages. It begins as a haematoma within a muscle and is confined by its tendinous attachments. This haematoma may remain localised or may dissect between the muscle and fascia. At this stage no radiological changes are seen. In the second stage, the increase in size of the haematoma presses on the cortical bone, impairs periosteal blood supply and thins the cortex. Finally the pressure necrosis of the cortex in conjunction with the elevated periosteum from subperiosteal haemorrhage forms the pseudotumour.<sup>1,5</sup> A pseudotumour may remain asymptomatic for years and then suddenly bleed and rupture.

The femur appears to be the most common site, accounting for slightly over one third of reported cases. The pelvis is a close second accounting for slightly under one third of reported cases.<sup>3</sup> Pseudotumours of the small bones of the hands and feet are also common. Two types of pseudotumours are recognised. The proximal type found in mature bone in adults is situated in the pelvis and femur. The distal type found in immature bone in children is situated in the small bones of the hands and feet, is usually multiple and is known to regress spontaneously with adequate treatment.

Early recognition of this complication is of paramount importance. A known history of haemophilia is very helpful in making the diagnosis of pseudotumour. It must be suspected where a cystic swelling is seen in a haemophiliac especially after a major muscle bleed. Calcification of soft tissue after a muscle bleed or failure of reabsorption of a mass must arouse a suspicion of pseudotumour formation. Conservative methods of diagnosis like aspiration and needle biopsy only complicate the disease further for they leave fistulous tracts, untreated surgical scars and are prone to secondary infection. Radiological features of soft tissue swelling with coarse calcification, periosteal elevation, and new bone formation with bone destruction giving a "soap bubble" appearance are diagnostic. These features may not be seen in early formation of the pseudotumour.

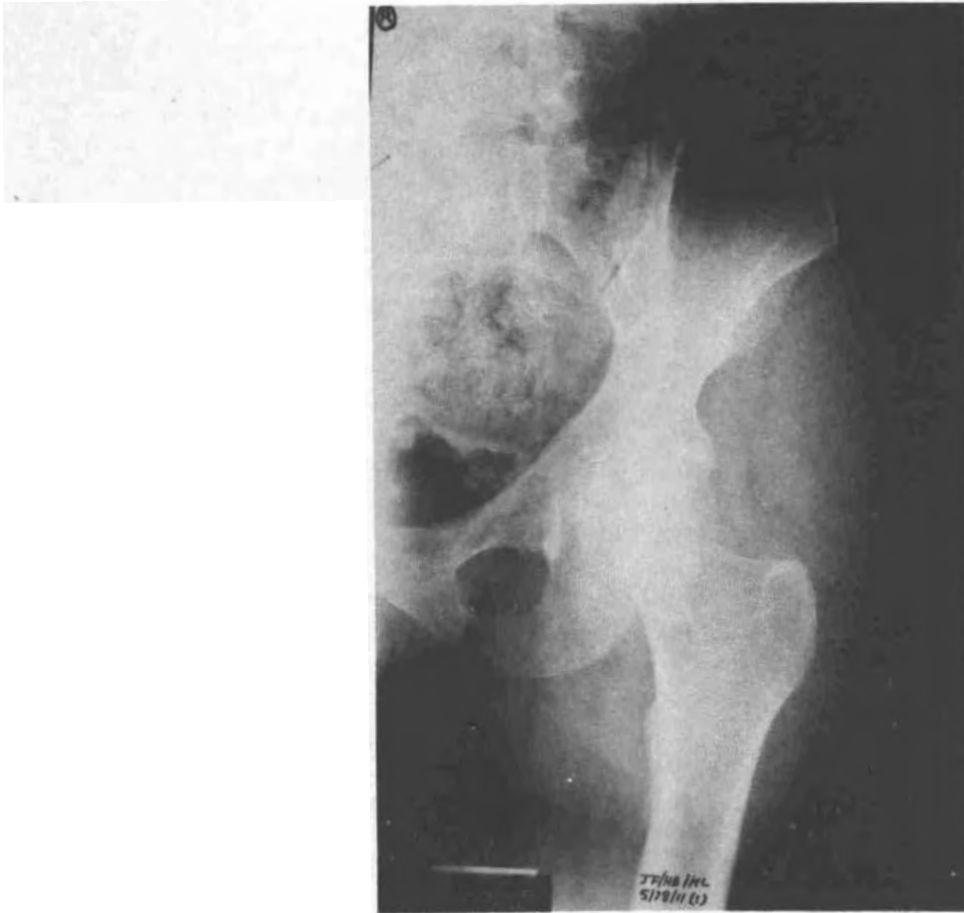
Diagnosis especially in the early stage is difficult. Periosteal elevation at an early stage has to be differentiated from osteomyelitis, Ewing's tumour, osteogenic sarcoma and metastatic neuroblastoma. Osteolytic bone destruction is difficult to differentiate from the osteolytic lesions of primary sarcoma, chondroma, tuberculosis, coccidiomycosis, syphilitic gamma, echinococcosis, chondroblastoma and metastatic neoplasm.

The pseudotumours can be treated conservatively, surgically or with radiation therapy.

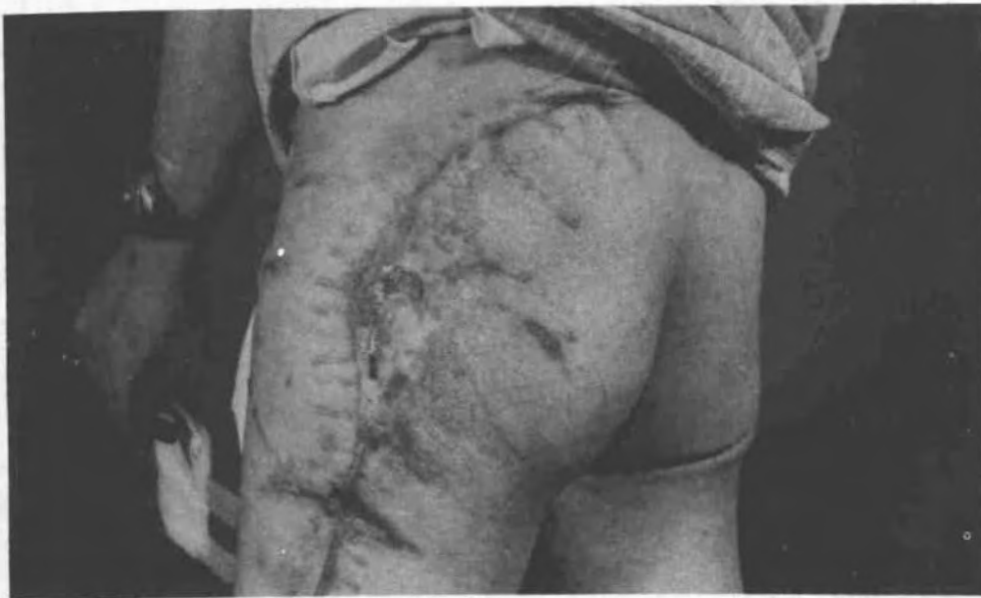Conservative management involves immobilisation of the affected part by means of plaster of Paris casts, splints or calipers. Replacement therapy to raise the factor level to a level of 50% is given till all evidence of haemorrhage has subsided.<sup>6</sup> Should size increase despite this, then surgery is the treatment of choice, but this should only be done at centres experienced in haemophiliac surgery.<sup>6</sup>

Surgery involves excision of the cyst or in some cases where the limb may be endangered by progressive neural and vascular compression, amputation of the affected limb has to be considered.

The long term effects of radiation, especially in children, has to be considered seriously prior to treatment by radiation. Aspiration of the tumour is contraindicated as it leaves fistulous tracts which are open to infection and death from sepsis.<sup>6</sup>



**Fig. 5 :** *Case 2 : Radiograph of left pelvis with soft tissue mass lateral to left hip and ileum.*



**Fig 6 :** *Case 2 : Unhealed surgical wound with discharging sinus.*

Both our cases illustrate the failure of early recognition and inadequate management of pseudotumour due to lack of facilities and therapeutic material. Our first case defaulted treatment for one year. The natural history of the pseudotumour and its complications are well demonstrated here due to inadequate and late treatment from the time of diagnosis. The second case had a shorter history and did not progress beyond the first stage of development of a pseudotumour. In both cases the large tumour mass led to ischemia of the overlying skin with ulceration and haemorrhage. Repeated haemorrhage led to enlargement of the pseudotumour, rupture, sinus formation and subsequent infection. Chronic blood loss from the sinuses in the first case led to fairly severe anaemia. Mechanical effects of the pseudotumour was seen in the first case where there was destruction of the tarsal bones as well as the muscles and tendons around the ankle. Both cases had hepatitis B and demonstrated a mild haemolytic jaundice, as a result of repeated transfusions. Surgery was resorted to when conservative management failed.

These two cases clearly demonstrate the importance of early and adequate treatment of all muscle bleeds in haemophiliacs. Today when FVIII concentrate is readily available the de-

velopment of a pseudotumour is indication of inadequate management of haemophilia.

#### ACKNOWLEDGEMENTS

We wish to thank Mr. Charles Abraham for the photography and Mrs. H. Kok for typing the manuscript.

#### REFERENCES

1. de Valderrama JAF, Matthews JM. The haemophilic pseudotumour or haemophilic subperiosteal haematoma. *J Bone Joint Surg* 1965; 47B: 256–65.
2. Starker L. Knochenusur durch ein hamophiles subperiostales Hamatom. *Mitt Grenzgeb Med Chir* 1918; 31: 381–415.
3. Jensen PS, Putman CE. Hemophilic pseudotumour. Diagnosis, treatment and complications. *Am J Dis Child* 1975; 129: 717–9.
4. Gilbert MS. Characterizing the hemophilic pseudotumor. *Ann NY Acad Sci* 1975; 240: 311–5.
5. Gwinn JL, Lee FA. Radiological case of the month. *Am J Dis Child* 1974; 128: 697–8.
6. Ahlberg AKM. On the natural history of hemophilic pseudotumor. *J Bone Joint Surg* 1975; 57A: 1133–6.