

AMYLOIDOSIS IN MALAYSIAN ABORIGINES (ORANG ASLI)*

LM LOOI MBBS, MPath** AND K PRATHAP MD, MRCPath***

Summary

Material from 334 consecutive autopsies on Orang Asli subjects performed in the University Hospital, Kuala Lumpur between May 1967 and June 1978 was examined for amyloidosis. Nine positive cases were found, all in patients above 40 years of age, giving an age-corrected incidence of about 9%. In 6 cases, amyloidosis was probably secondary to tuberculosis. The remaining 3 cases exhibited a pericollagenous distribution characteristic of primary amyloidosis. Involvement of the heart and lungs was prominent. However, there were considerable similarities in the distribution and staining properties of the amyloid in the 2 groups. Though both the heart and kidney were frequently affected, the kidney was the most common organ to give rise to clinical symptoms. Infection probably plays a major contributory role in amyloidosis in the Orang Asli.

While amyloidosis is uncommon in Western populations(1, 2) it occurs more frequently in Africa(3). Reports from India indicate that it is not as uncommon as was previously believed(4, 5) and in Papua New Guinea it has been found in over 7% of routine autopsies(6). Published information on amyloidosis in South East Asia is scanty, but is generally believed to be uncommon. Muir & Thomas(7) found only 2 cases of amyloidosis in 10,000 adult autopsies in Singapore. On the basis of autopsy data, there appears to be a relatively high incidence of amyloidosis among the Orang Asli (aborigines) of West Malaysia. This paper reports our findings.

MATERIALS AND METHODS

Autopsies were performed on 334 Orang Asli subjects in the University Hospital, Kuala Lumpur, in the 11 year period between May 1967 and June 1978. Gross findings were recorded. Representative blocks from the major organs, including normal and abnormal areas, were fixed in 4% buffered formaldehyde and embedded in paraffin. Sections were stained with haematoxylin and eosin. Where indicated, special stains were employed. In each case screening for amyloid included light microscopic examination of sections stained with Congo red, from at least 1 and frequently all of

4 organs, namely, the heart, kidney, liver and spleen. Amyloid was recognised as amorphous, eosinophilic extracellular material which stained rose-pink with Congo red and exhibited a green birefringence under cross-polarised light. Sections of all available tissue from positive cases were stained with haematoxylin and eosin, Congo red, crystal violet and thioflavine T, and examined for the presence and histological distribution of amyloid and coexisting pathology. Formalin fixed tissue from the liver of a massively involved case was fixed in glutaraldehyde, postfixed in 1% osmium tetroxide, embedded in epon and ultrathin sections were examined with a Hitachi HS8 electron microscope operated at 50 KV. Clinical data were obtained from case summaries.

RESULTS

Incidence

In 334 consecutive autopsies on Orang Asli subjects in the University Hospital, nine cases of generalised amyloidosis were detected, giving an overall incidence of 2.7%. However, all 9 cases were in the older age group, giving an incidence of 8.9% in subjects above 40 yr of age. Seven patients were male and 2 were female. The mean age was 51.5 yr and the mode 50 years. The youngest patient was 44 yr and the oldest was 67 yr of age.

*Reprinted by permission of its Editor, from PATHOLOGY, Volume 11, October, 1979.

**Lecturer, Department of Pathology, Faculty of Medicine, University of Malaya, Kuala Lumpur (Address for reprint requests).

***Professor, Department of Pathology, Faculty of Medicine, University of Malaya, Kuala Lumpur.

Staining properties

The amyloid in all 9 cases exhibited similar staining properties. With the haematoxylin and eosin stain, amyloid was seen as a homogeneous, eosinophilic material. It stained rose-pink with Congo red and under cross-polarised light had a fibrillar structure which exhibited a green birefringence. It showed a violet metachromasia with the crystal violet stain and a greenish-yellow fluorescence under ultra-violet light with thioflavine T. Electron microscopy performed on one case showed the typical fibrillar structure of amyloid (Fig. 1).

Pattern of amyloidosis

In the 9 cases, no inflammatory response was seen in relation to the amyloid and no differences were evident in the type of organ involved. However, differences were noted in the severity of involvement and the site of amyloid deposition in the various organs. Based on these and other associated conditions, the 9 could be separated into 2 groups.

Group I Group I consisted of 6 patients, four of whom had active tuberculosis. The remaining 2 had lobar pneumonia as well as severe pleural adhesions and pulmonary fibrosis consistent with previous pulmonary tuberculosis. Besides these, incidental findings included a porocephalid granuloma in the liver of one case and schistosomiasis in another. The cases in this group could readily be accepted as exhibiting secondary amyloidosis. Organ involvement in this group was mild to moderate. In the affected organs, amyloid was detected in the walls of small blood vessels at and around the intima, spreading outwards into the media as the severity of involvement increased.

Of 6 spleens examined, 3 were affected. In two of them amyloid was present not only in the walls of blood vessels but also along sinusoidal walls and the network of the white pulp (Fig. 2). Three out of 5 kidneys examined were affected. Amyloid was seen in the walls of small vessels and glomerular arterioles with mild to massive replacement of glomeruli. A periglomerular distribution due to deposition along the basement membrane of Bowman's capsule was frequently seen. Amyloid was also detected along the tubular basement membrane and in the interstitium. No amyloid casts were seen. No parenchymatous involvement was detected

in the 6 livers. Amyloid was confined to the walls of the hepatic arterioles. In 3 out of 4 hearts examined, amyloid was present in myocardial vessel walls. There was no parenchymatous involvement. Five lungs were examined. Only in 1 case was a small blood vessel involved. Three out of 4 adrenals showed involvement of the capsular arterioles and venules. A vein in the medulla was occasionally affected. In 1 of the 3 thyroid glands examined, amyloid was present in vessel walls, along the follicular basement membrane and in the interstitium. Of 2 tongues examined one had amyloid which was deposited along reticulin fibres surrounding adipose cells, in subepithelial connective tissue as well as in vessel walls. Where the pancreas, intestine or lymph nodes were affected, amyloid was confined in vessel walls. In one case where the central nervous system was examined, no amyloid involvement was found.

Group II In Group II, all 3 cases were similar in that organ involvement was massive and amyloid was seen in the adventitia of small and medium-sized blood vessels spreading inwards towards the media as the severity of involvement increased. This conformed to the pericollagenous pattern described by Heller *et al.* (8) as indicative of primary amyloidosis (Figs. 3 and 4). The contributory role of infection was difficult to assess. One case had no obvious infections. One had elephantiasis due to chronic filariasis and one had evidence of pulmonary fibrosis attributable to pulmonary tuberculosis.

Compared to Group I, cardiac involvement was severe in all 3 cases. Blood vessels of the epi-, endo- and myocardium were affected. Amyloid was deposited around epicardial adipose cells and along the sarcolemma of myocardial cells. Nodular deposits were also seen in the epicardium, endocardium and valves. In all 3 cases, involvement of the lung was prominent. Amyloid was seen in the walls of vessels, along alveolar septa, basement membrane of bronchial epithelium and mucous glands and in the lamina propria of bronchial mucosa. There was no parenchymatous involvement in the 2 spleens examined and amyloid was confined to the walls of vessels. Where the kidney, liver, thyroid, tongue, adrenal, intestine, pancreas and lymph nodes were affected, the distri-

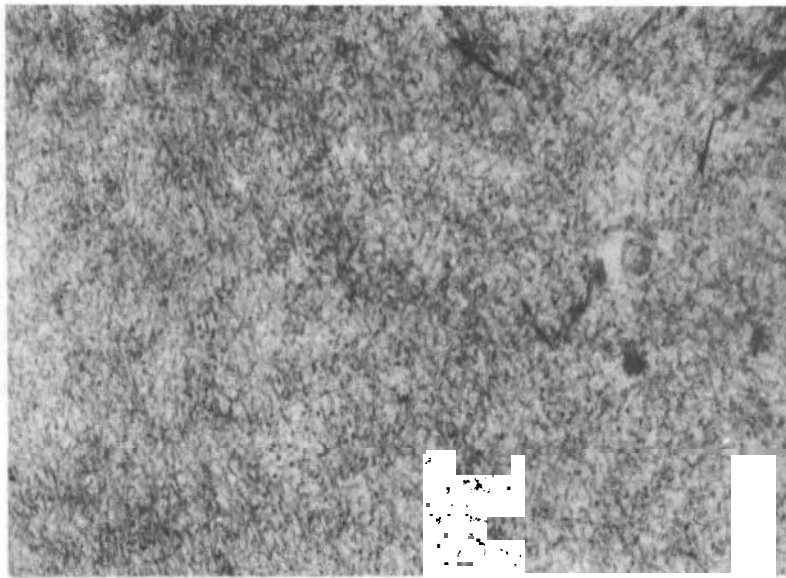


Figure 1: *Electron micrograph of amyloid deposit in a massively involved liver, showing typical amyloid fibrils. X 60,000*




Figure 2: *Amyloid deposits in splenic vessel walls, along the network of the white pulp and sinusoidal walls of a case from group 1. H & E X 134.*

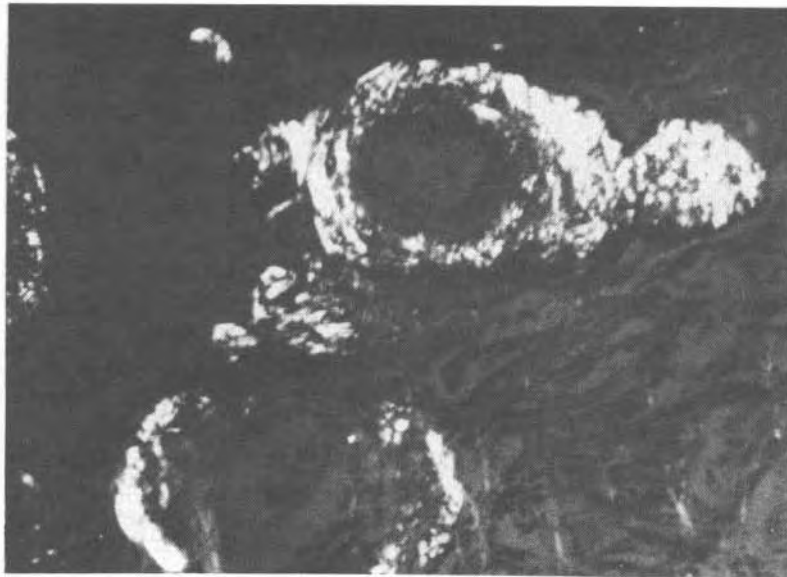

Figure 3: *Renal arteries with a pericollagenous distribution of amyloid, stained with Congo red and photographed under cross-polarised light. Areas showing the characteristic green birefringence appear white. Congo red – polarised light X 134.*

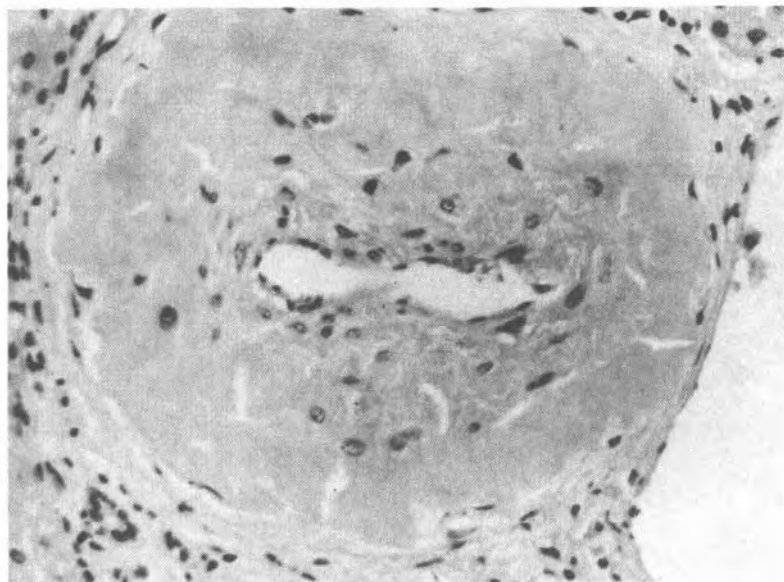


Figure 4: *Pericollagenous distribution of amyloid in hepatic arteriolar wall of a case from group II. Congo red X 330.*

but ion of amyloid was similar to Group I. In one parathyroid gland examined, involvement was remarkably severe, resulting in massive replacement of most of the gland by amyloid (Fig. 5). In two cases where the central nervous system was examined, amyloid was present in an occasional arteriole in the choroid plexus. Vessels in the brain were spared.

Clinical manifestation

The heart and kidney were the most frequent organs affected irrespective of group (Table 1). In group I, the prominent clinical features were those of infection. The patients died of miliary tuberculosis, bacterial pneumonia or septicaemia. Two cases showed clinical evidence of congestive cardiac failure terminally and this was probably secondary to severe pulmonary infection. All 3 cases of Group II had histological evidence of cardiac and renal involvement as well as clinical evidence of renal involvement. One had nephrotic syndrome and 2 died in renal failure.

DISCUSSION

The Orang Asli Hospital at Gombak, Kuala Lumpur, serves the entire Orang Asli population of West Malaysia. It is a base hospital to which patients from jungle medical posts are sent and admits all Orang Asli patients

without discrimination(9). However, the Orang Asli are a shy people. Some may resist admission and there are those with terminal illnesses who prefer to return to their jungle homes to die. Available for autopsy are mainly unclaimed bodies which constitute about 68% of the total number of hospital deaths(10). The autopsies are performed in the University Hospital, Kuala Lumpur. Because of these factors of selection, the findings in this study may not be representative of the Orang Asli population as a whole. Nevertheless, it raises the strong suspicion that amyloidosis is relatively common among the Orang Asli.

In Singapore, where the population is predominantly Chinese, Muir & Thomas(7) found only 2 cases of amyloidosis in 10,000 adult autopsies. Though the prevalence of this disease in the non-Aboriginal population of West Malaysia is generally believed to be low, there is as yet no published information confirming this.

The high incidence of amyloidosis observed in the Orang Asli, who are a very distinct and isolated group of people in West Malaysia, may be related to their genetic make-up or to the special environmental factors to which they are exposed. The Orang Asli, numbering about 53,000 at the 1969 census, live in the jungles of West Malaysia. They consist of 3 main groups,

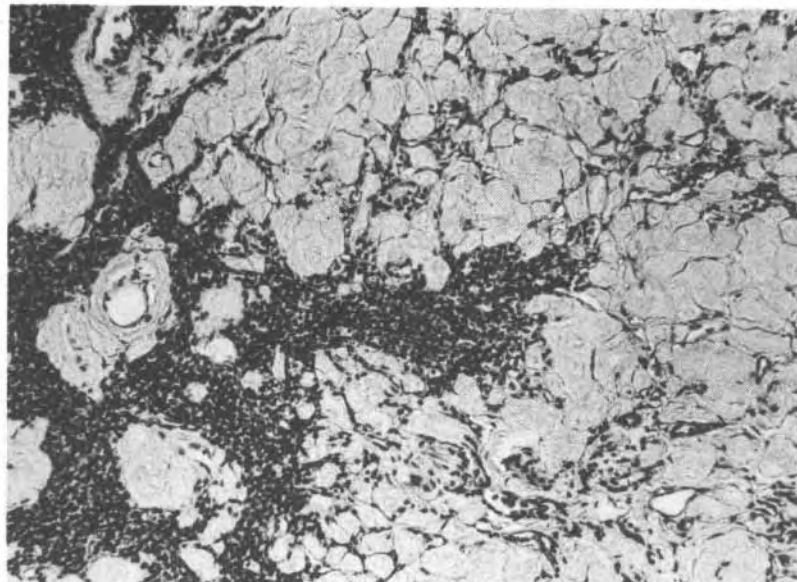


Figure 5: Massive amyloid involvement of a parathyroid gland. The amyloid appears pale. H & E X 134.

TABLE I
FREQUENCY OF ORGAN INVOLVEMENT IN 9 ORANG ASLI
SUBJECTS WITH GENERALISED AMYLOIDOSIS

<i>Organ</i>	<i>No. Examined</i>	<i>No. Positive</i>
Heart	7	6
Kidney	8	6
Spleen	8	5
Liver	8	5
Lymph node	7	4
Lung	8	4
Adrenal	6	5
Thyroid	6	4
Pancreas	5	5
Gut	5	4
Brain	3	2
Tongue	2	2
Prostate	2	1

the Senoi, Negrito and Melayu Asli, each comprising several tribes. The Senoi are agriculturists who practise shifting cultivation on mountain slopes, hunt with blow-pipes and poison darts and trap animals for food. The Negrito are nomads who dwell in temporary shelters and feed on jungle roots and animals. The Melayu Asli live in groups in the lowland and mangrove swamp areas. Though some interact with small nearby towns, most depend on the jungle for their livelihood. Because of their primitive life, bacterial and parasitic infections are common among the Orang Asli (11, 12). Tuberculosis and other infections account for about 75% of the Orang Asli deaths (10, 13). The serum immunoglobulin levels in the Orang Asli have been reported to be significantly higher than those of the local non-aborigine population (14, 15).

A mounting interest in amyloidosis in the recent years has stimulated much work in the pathogenesis of this disease. A strong relationship between disturbances of the immune response and the formation of amyloid has been pointed out (16-18). Franklin and Zucker-Franklin (18) postulated that "amyloid is likely to occur in situations where the size of the antigenic stimulus is excessive compared to the capacity of the immune system or where the immune system has escaped from normal control mechanisms". It is conceivable that the continuing infections so prevalent in the Orang

Asli contribute to amyloidogenesis, through chronic stimulation and demands on the immune system. Tuberculosis appears to be a major aetiological agent. It is interesting to note that amyloidosis was not present in the 2 cases of multiple myeloma in this series. However, tissue from a 44 year old Orang Asli man with clinical and histological evidence of multiple myeloma showed renal tubular casts which exhibited all the tinctorial properties of amyloid. Electron microscopy showed characteristic amyloid fibrils. There was no evidence of tissue involvement by amyloid. Amyloid casts in multiple myeloma have been reported to occur independently of the presence or extent of amyloidosis in other organs (19). The prevalence of immunological disturbances and plasma cell dyscrasias among the Orang Asli has not been well documented although, as has been mentioned, they often have raised serum immunoglobulin levels. Further studies into their immunological status are likely to contribute considerably to the understanding of amyloidogenesis in these people.

Cooke & Champness (6) reported variable metachromatic staining in cases of amyloidosis in Papua-New Guinea. Unlike their observations, the staining properties of amyloid in our cases are consistently uniform. Though both the heart and kidney were frequently affected, the kidney was the most common organ to give rise to clinical symptoms. This is consistent

with findings in India(4) and Papua–New Guinea(6).

A classification into primary and secondary amyloidosis is adopted with reservation because of difficulty in assessing the contributory role of infection in these subjects. Although we were able to observe two morphological

patterns which conformed in some aspects to what has been generally described as primary and secondary amyloidosis, we are in agreement with those who have pointed out the similarity in amyloid distribution in primary and secondary amyloidosis(6, 20, 21).

REFERENCES

1. Patrassi G. Primary amyloidosis. *Postgrad Med J* 1965; 41: 247–51.
2. Anonymous. Diagnosis of amyloidosis. *Br Med J* 1966; 2: 1090.
3. Edington GM, Mainwaring AR. Amyloidosis in Western Nigeria. *Pathol Microbiol* 1964; 27: 841–7.
4. Reddy CRRM, Sulochana G, Devi CS. Amyloidosis – a prospective study. *J Indian Med Assoc* 1971; 56: 301–4.
5. Mathur BB, Jhala C. Amyloidosis. An emphasis on increasing incidence in India. *Indian J Pathol Bacteriol* 1964; 7: 133–45.
6. Cooke RA, Champness LT. Amyloidosis in Papua – New Guinea. *Med J Aust* 1970; 2: 1177–84.
7. Muir CS, Thomas MA. Geographical pathology of amyloidosis in Singapore. *Pathol Microbiol* 1964; 27: 848–9.
8. Heller H, Missmahl HP, Sohar E, Gafni J. Amyloidosis: its differentiation into perireticulin and peri-collagen types. *J Pathol Bacteriol* 1964; 88: 15–34.
9. Bolton JM. Medical services to the aborigines in West Malaysia. *Br Med J* 1968; 2: 818–23.
10. Sumithran E, Prathap K. Hepatocellular carcinoma in the Malaysian Orang Asli. *Cancer* 1976; 37: 2263–6.
11. Polunin I. The medical natural history of Malayan aborigines. *Med J Malaya* 1953; 8: 55–174.
12. Dunn FL. Intestinal parasitism in Malayan aborigines (Orang Asli). *Bull WHO* 1972; 46: 99–113.
13. Prathap K, Montgomery GL. Aortic and coronary atherosclerosis in the Malaysian Orang Asli. *Pathology* 1974; 6: 255–61.
14. White JC, Frank AO, Toh BH, Lau KS. The pattern of systemic lupus erythematosus in 38 patients in West Malaysia, particularly of haematological manifestations. *Malaysian J Pathol* 1978; 1: 33–42.
15. Lim VKE, Moosdeen F, Nagappan N. Serum immunoglobulin levels in the Semai. *Med J Malaysia* 1977; 31: 288–91.
16. Glenner GG, Page DL. Amyloid, amyloidosis, and amyloidogenesis. *Int Rev Exp Pathol* 1976; 15: 1–92.
17. Glenner GG, Terry WD, Isersky C. Amyloidosis: its nature and pathogenesis. *Semin Hematol* 1973; 10: 65–86.
18. Franklin EC, Zucker-Franklin D. Current concepts of amyloid. *Adv Immunol* 1972; 15: 249–304.
19. Limas C, Wright JR, Matsuzaki M, Calkins E. Amyloidosis and multiple myeloma. A reevaluation using a control population. *Am J Med* 1973; 54: 166–73.
20. Symmers W St C. Primary amyloidosis: review. *J Clin Pathol* 1956; 9: 187–211.
21. Anonymous. Amyloidosis and the kidney. *Br Med J* 1973; 2: 322–3.