Malaysian J Pathol 2019; 41(3) : 345 – 350

CASE REPORT

Salivary gland anlage tumour of the nasopharynx: A case report and review for histopathological characteristics

Kayhan BAŞAK[1], Ömer GÜNHAN[2], Sevtap AKBULUT[3], Sedat AYDIN[4]

[1]University of Health Science, Kartal Dr.Lütfi Kırdar Education and Research Hospital, Department of Pathology, İstanbul, Turkey. [2]Department of Pathology, Tobb ETÜ Hospital, Ankara, Turkey. [3]Yeditepe University, Department of Otolaryngology Head and Neck Surgery, İstanbul, Turkey. [4]İstanbul University, İstanbul Medical Faculty, Department of Oral and Maxillofacial Surgery, İstanbul, Turkey

Abstract

Introduction: Congenital salivary gland anlage tumour of the nasopharynx is a lesion which usually presents with nasal and upper respiratory tract obstruction in the neonatal period. Timely diagnosis is essential to prevent the occurrence of respiratory complications in later childhood. *Case Report:* We present a 8-year-old boy complaining from difficulty in breathing and breastfeeding in the neonatal period due to an adenoid-like nasopharyngeal mass. Histological examination revealed solid and cystic squamous nests and numerous duct-like structures within collagenised stroma. Both epithelial and myoepithelial differentiation were noted in the tubular component. *Discussion:* A review of the clinical and histopathological features of published cases revealed that ancient lesions showed more prominent and complex epithelial component and more collagen rich stroma. We would like to suggest the possibility of salivary gland anlage tumour to be considered in the differential diagnosis of neonatal respiratory distress cases.

Keywords: Salivary gland, anlage tumour, congenital, nasopharynx, childhood, histological characteristics

INTRODUCTION

Among the causes of nasal obstruction in the neonatal period, salivary gland anlage tumour (SGAT) is remarkable because of its hamartomatous nature being an uncommon cause of neonatal distress.[1] This seldom, but not a rare entity leads to respiratory distress and/or feeding difficulties early in life.[1-10] There were not any cases, untreated with continued respiratory complications until late childhood and all cases in the literature were children diagnosed within the first year of life.[1-18] Our patient was significantly older than the previous cases in the literature and had been untreated suffering with these symptoms until the age of 8 years. Except for a few articles in which histopathological features were described in detail,[7,8] the literature revealed limited histopathological features of SGAT.[1-6,11-14] We aimed to describe all histopathological features of this unusual lesion and compare the histopathological features of our case with reported cases in the literature.

CASE REPORT

An eight-year-old boy was presented with respiratory distress since birth, following delivery. There was difficulty during breastfeeding and foam in the mouth, shortness of breath, snoring and oral breathing while sleeping. Surgery was immediately recommended, but postponed because of anemia. He used sea water intervally of up to 8 years for nasal congestion, without benefit. Until the age of eight, an operation was recommended every time at the recurrent consultations, but the parents did not accept the operation. Parents did not note an impression due to the progressive growth of the mass. No imaging technique was used to investigate the mass. Adenoidectomy was performed with a diagnosis of adenoid vegetation and 2cc of

Address for correspondence: Doç.Dr.Kayhan Başak, Kartal Dr.Lütfi Kırdar Eğitim ve Araştırma Hastanesi, Patoloji Kliniği, Şemsi Denizer Cad. E-5 Karayolu, Cevizli Mevkii, 34890 Kartal, İstanbul, Türkiye. Tel: +90 216 4413900. Fax: +90 216 3520083. Email: drkayhanbasak@yahoo.com/ kayhan.basak@saglik.gov.tr

adenoid tissue was curetted. Under the adenoid tissue, a firm mass was detected and resected so that no residue was remained. The excised material was a gray coloured, firm, solid mass with a dimention of 2.3 x 1.7 x 1.4 cm.

Histological examination revealed a nodule covered by a non-keratinising squamous epithelium (Fig. 1). The stroma was collagen rich, hypocellular and have focal hypercellular areas. The epithelial component was variable and prominent. There were complex and branching ductal structures lined with columnar to cuboidal epithelium, connected to surface squamous epithelium (Fig. 2a). Some of the dilated duct-like structures had papillary projections (Fig. 2a and 2d). In the ductal columnar epithelium, a common squamous metaplasia forming keratin-filled multiple cysts was seen (Fig. 1 and 2b). The granular layer was observed focally in the squamous epithelium with cystic structures. There were no heterologous stromal elements. Calcifications in the stroma and in the lamellar keratin material in cystic structures which lined with squamous epithelium were present (Fig. 2c). Mitosis, nuclear or cytological atypia and necrosis were not observed in both epithelial and stromal cells. The stroma, which consisted of spindle cells, contained enriched collagen bundles, hypocellular areas and myxoid focuses. The immunohistochemical profile of the case was shown in Table 1. No clinical recurrence was observed during 69-months follow-up and the patient is still under control.

DISCUSSION

SGAT is a tumour characterised by its clinical presentation, symptoms and specific histologic features. Although a few cases have been reported in the literature, similar clinical findings, symptoms and histologic features suggest that SGAT is a unique entity. Almost all cases, except for our case, were newborn diagnosed under 1 year old. There is pronounced male dominance, and the male/female ratio was 22/5, including our case. In 22 of the 27 cases, the mass was nasopharyngeal. Whereas it mass was located in a nasal cavity in one case,[3] pharynx in two cases,[4,7] posterior pharyngeal wall and/or posterior septum in one case,[5] and oropharynx in one case.[10] It appears to have been accepted as an embryonic development, due to the existence of ductus like structures and glandular structures continuing with surface squamous epithelium.[7,19] No genetic abnormalities were detected in an individual genetic analysis done by Vranic *et al*..[2]

All previous cases were presented as a nodular mass, which was neatly confined in the tissue. Squamous epithelium was covering the surface of the nodular structure in the majority of the cases. The stroma consisting of spindle cells was multinodular with hypocellular and hypercellular areas. The epithelial component showed glandular, ductal and tubular structures variably continued with flat multi-layered epithelium at one or more focuses. The epithelial component also consisted glandular,[3,5-9,13,16,19] ductal[1-5,7-9,11,14,15,17] or tubular [2,5-8,10,15] structures lined with columnar and/or cubic epithelium.[2,7,9] Moreover in some cases, solid islands,[3,7,8,10,14,17] cords[12,13] or nests[1,3,5,7,8,12-14] were defined. Out of the newborns, three cases were reported as 12 months,[2] 3.5 months[7] and 6 weeks old.[3] The findings of the 3.5-month-old case was defined totally in a review and findings were not specified.[7] There were no significant differences in the histological characteristics of the two cases, whose ages were relatively different from the others.[2,3] Our patient is strikingly older than the previously reported cases and was covered with all the features described histopathologically in the literature. Moreover, this case has prominent epithelial component with ductus, tubulus, glandular and papillary structures and also contains more common papillary structures lining with cuboidal/columnar epithelial than those described in other cases (Fig. 2a and 2d). Although squamous epithelium was defined as metaplastic in some cases,[9,16] all cases had squamous epithelium as nests, cords or cystic structures. Lamellar keratinous material and calcification[8,16] could be seen in the lumen of squamous epithelium lining macro- and microcystic structures. It seems that common squamous metaplasia was probably due to the age of the lesion. Squamous cystic structures[3,7,8,10,12,16] and calcification[8,16] were not associated with age in the cases reported in the literature. In our case, multiple squamous cystic structures and multiple calcification foci were present in the stroma and squamous epithelial component. Although stroma showed variable cellularity, significant collagen bundles were seen. The epithelial component is always positively stained with several keratin markers[2-5,8,9,12,14,16] and variable staining with epithelial markers has been reported in stromal cells.[2-4,8,9] All cases were S100 negative consistently in the stromal and epithelial cells, except for the scattered S100 positive stromal cells in one case.[4] In our case, there were several foci of positive spindle cells with S100 and SMA in the myxoid area of the

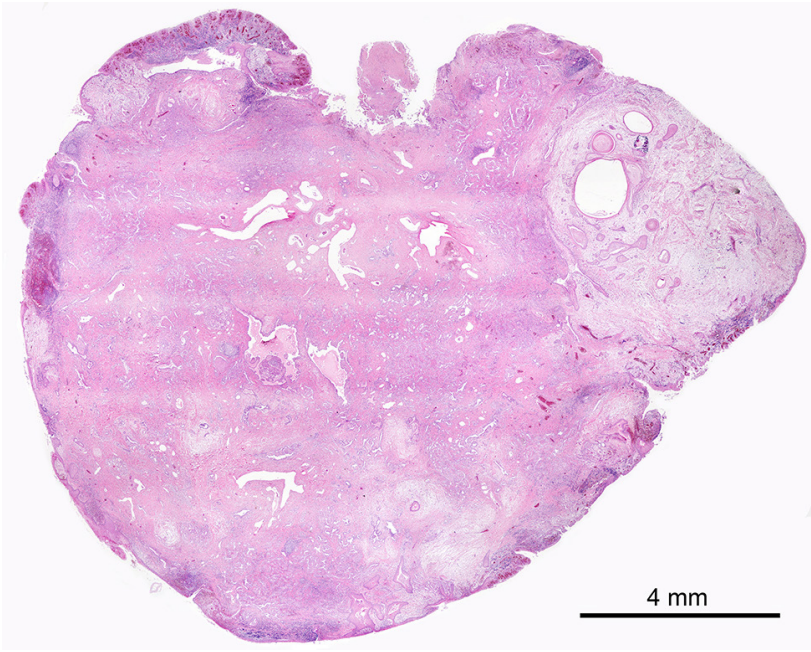

FIG. 1: Panoramic view of the lesion. Collagen rich stroma with hypocellular nodule is composed spindle cells. Prominent epithelial ductal, glandular structures and cystic spaces (H&E, x40).

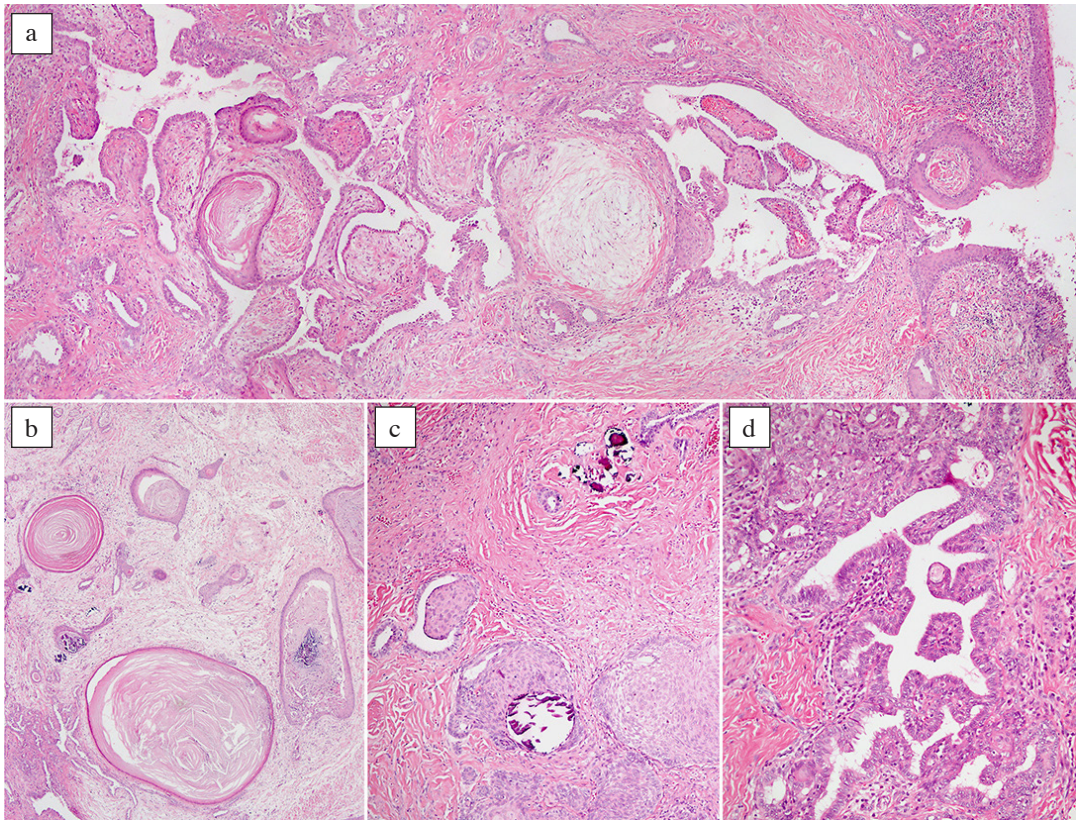

FIG. 2: (a) Complex ductal structures that contain papillary foldings and connected with squamous epithelium on the surface (H&E, x100). (b) Variated sized cysts lined by squamous epithelium (H&E, x200). c) Calcification in squamous epithelial nests and in stroma (H&E, x200). d) Papillar projections lined with cuboidal to columnar epithelium (H&E, x200).

TABLE 1: Immunohistochemical profile of case

Markers	Brand	Clone	Dilution	Origin	Squamous Epithelium	Epithelium of Ductal Structures	Epithelium of Glandular Structures	Epithelium of Papillary Structures	Stromal cells
CDX2	Cell Marque	EPR2764Y	1/300	CA, USA	-	-	-	-	-
CEA	Leica Biosystems	Novocastra 12-140-10	RTU	Newcastle, UK	+	+	+	FW	-
CK	Genemed	AE1/AE3	1/100	CA, USA	+		+	+	-
CK 5/6	Cell Marque	D5&16B4	1/100	CA, USA	MSE +	BL	F BL	-	-
CK14	Cell Marque	LL002	1/100	CA, USA	+	BE+LE	BE	F+	-
CK19	Thermo	A53-B/A2.26	1/100	MA, USA	+	+	+	+	-
CK20	Leica Biosystems	Novocastra-561	1/100	Newcastle, UK	-	-	-	-	-
CK7	Thermo	OV-TL 12/30	1/150	MA, USA	-	+	+	+	-
EMA	Thermo	E29	1/500	MA, USA	W	+	+	+	-
HMWCK	Genemed	34ßE12	1/100	CA, USA	+	+	+	+	-
Ki67	Biocare	SP7	1/100	CA, USA	BE	L	L	L	L
Laminin	Thermo	Polyclonal	1/200	MA, USA	BL	BL	BL	BL	Vascular BL
MUC5AC	Scytek	45M1	RTU	UT, USA	-	F	F	-	-
p53	Biogenex	D07	1/800	CA, USA	Wild	Wild	Wild	Wild	Wild
p63	Biocare	4A4	1/100	CA, USA	F	F basal	F basal	F basal	-
S100	Genemed	Polyclonal	1/100	CA, USA	-	F basal	-	F basal	PN
SMA	Thermo	1A4	1/800	MA, USA	-	-	-	-	+
Vimentin	Leica Biosystems	Novocastra-V9	1/800	Newcastle, UK	-	+	+	F	+

F: focal, W: weak, L: low proliferative index, H: high, MSE: metaplastic squamous epithelium, BL: basal lamina, BE: basal epithelium, LE: luminal epithelium, RTU: ready to use, PN: Periphereal nerve.

TABLE 2: Histological findings of epithelial components of the cases

	Age	Gender	Diagnosis	Surface, Over lining epithel	Connected to the surface epithelium	Glandular formation	Glandular epithelium	Ductular structures	Ductal epithelium	Tubular structures	Tubular epithelium	Papillar structures	Papillary epithelium	Squamous (Epidermal) differentiation	Cysts	Cystic structures epithelium	Atypia	Mitosis	Calcification	Infarction, necrosis	Hemorragi
Başak et al.	8y	M	SGAT	NK-Sq	+	+	cu/co	+	cu/co	+	cu/co	+	cu/co	+	+	Sq	-	-	+	-	+
Boccon-Gibod[8]	2-8d	2M	SGAT	NK-Sq	+	+		+		+		+		+	+	Sq		Numerous	+		
Gauchotte[3]	NB	M	SGAT	Sq		+		+						+	+	Sq	-	Rare			
Gauchotte[3]	6w	F	SGAT	Sq	+	+		+						+	+	Sq	-	-			
Dehner[7]	NB-3,5m	6M, 2F	SGAT	NK-Sq		+		+	cu			+		+	+	Sq					
Bondeson[9]	NB	M	SGAT	NK-Sq	+	+	cu	+	cu					+							+
Herr[5]	2d	M	SGAT		+	+		+		+				+							
Herrmann[12]	NB	M	SGAT	NK-Sq	+					+				+	+	Sq	-	-		F	+
Michal[16]	NB	M	SGAT			+								+	+	Sq		Exceptional	+	WS	+
Antunes [1]	NB	M	SGAT	NK-Sq	+			+						+				-			
Mogensen[11]	2w	F	SGAT	NK-Sq				+						+			-	-			
Cohen[4]	NB	M	SGAT	NK-Sq				+						+			-	Not prominent		-	
Vranic[2]	12m	M	SGAT	Sq				+	cu/ lco	+	cu/lco			+							
Marien[6]	NB	M	SGAT	NK-Sq		+				+				+			F in NK-Sq	Only few			
Ibrahim[15]	NB	F	SGAT					+		+	dl			+					+		
Swayampakula[17]	NB	M	SGAT					+						+							
Daniller[14]	NB	US	SGAT					+						+							
Stillwater[13]	NB	M	Probable SGAT			+								+						L	

SGAT: Salivary gland anlage tumor, US: unspecified, cu: cuboidal, co: columnar, lco: low columnar, PD: Poorly differentiated, WS: Widespread, Sq: Squamous, NK: Non-keratinized, L: localized, F: focal, dl: double layer, NB: newborn

stroma. p63 was positive in two cases,[5,14] but the positively stained cellular component was not specified. In our case, there were focal staining in all squamous, ductal, glandular and papillary epithelium.

The most important tumour in the differential diagnosis of SGAT is mucoepidermoid carcinoma (MEC). The tumour in this case is nodular and its surface is covered with non-keratinised epithelium. In SGAT, keratinous epithelial is mature and contains variable quantities of cystic structures filled with keratin and the most important feature in the differential diagnosis is the absence of mucinous cells, except for a case.[1] Also stromal nodules are not characteristic of the MEC. The fact that the symptoms did not progress until the age of 8, especially in the first years of our case, suggests that SGAT is not in a significant growth tendency. No recurrence was observed in the follow-up period between 6 months and 8 years in all cases. In a case, atypia in the some fragments of overlying non-keratinised squamous cell lining were reported which followed up for 10 months, without recurrence.[6]

CONCLUSION

It's clear that SGAT is a unique lesion with its localisation, symptoms and histological features. Ancient lesions show more prominent and complex epithelial component and more collagen rich stroma. Aging of lesion does not seems to have the tendency of growing.

ACKNOWLEDGMENTS

This study presented as a poster at "30th European Congress of Pathology" in Bilbao-Spain, 07-12 September 2018 (E-PS-11-025).

DECLARATION OF INTEREST

The authors report no declarations of interest.

REFERENCES

1. Antunes MB, Javia LR, Ransom ER, Kazahaya K. Salivary anlage tumor of the nasopharynx: A case report and review of the literature. *Int J* Pediatr Otorhinolaryngol Extra 2011; 6: 69-71.
2. Vranic S, Caughron SK, Djuricic S, *et al*. Hamartomas, teratomas and teratocarcinosarcomas of the head and neck: Report of 3 new cases with clinico-pathologic correlation, cytogenetic analysis, and review of the literature. BMC Ear Nose Throat Disord. 2008; 8: 8.
3. Gauchotte G, Coffinet L, Schmitt E, *et al*. Salivary gland anlage tumor: a clinicopathological study of two cases. Fetal Pediatr Pathol. 2011; 30: 116-23.
4. Cohen EG, Yoder M, Thomas RM, Salerno D, Isaacson G. Congenital salivary gland anlage tumor of the nasopharynx. Pediatrics 2003; 112: e66-9.
5. Herr MW, Williams SB, Cable BB. Pathology quiz case 1. Salivary gland anlage tumor (SGAT). Arch Otolaryngol Head Neck Surg. 2009; 135: 320-2.
6. Marien A, Maris M, Verbeke S, *et al*. An unusual tumour causing neonatal respiratory distress. B-ENT. 2012; 82: 149-51.
7. Dehner LP, Valbuena L, Perez-Atayde A, Reddick RL, Askin FB, Rosai J. Salivary gland anlage tumor ("congenital pleomorphic adenoma"). A clinicopathologic, immunohistochemical and ultrastructural study of nine cases. Am J Surg Pathol. 1994; 181: 25-36.
8. Boccon-Gibod LA, Grangeponte MC, Boucheron S, Josset PP, Roger G, Berthier-Falissard ML. Salivary gland anlage tumor of the nasopharynx: a clinicopathologic and immunohistochemical study of three cases. Pediatr Pathol Lab Med. 1996; 16: 973-83.
9. Bondeson L, Andreasson L, Olsson M, Rausing A. Salivary gland anlage tumor: cytologic features in a case examined by fine-needle aspiration. Diagn Cytopathol. 1997; 166: 518-21.
10. Har-El G, Zirkin HY, Tovi F, Sidi J. Congenital pleomorphic adenoma of the nasopharynx (report of a case). J Laryngol Otol. 1985; 99: 1281-7.
11. Mogensen MA, Lin AC, Chang KW, Berry GJ, Barnes PD, Fischbein NJ. Salivary gland anlage tumor in a neonate presenting with respiratory distress: radiographic and pathologic correlation. AJNR Am J Neuroradiol. 2009; 30: 1022-3.
12. Herrmann BW, Dehner LP, Lieu JE. Congenital salivary gland anlage tumor: a case series and review of the literature. Int J Pediatr Otorhinolaryngol. 2005; 69: 149-56.
13. Stillwater LB, Fee WE Jr. Squamous cell proliferative lesion of the nasopharynx in a newborn. Otolaryngol Head Neck Surg. 1980; 88: 240-7.
14. Daniller T, Goedhals J, Seedat R. Salivary gland anlage tumour – a rare cause of congenital nasal obstruction. S Afr J Child Health. 2014; 8: 31-3.
15. Ibrahim SA, Abdalla HA, El Hassan AM. Case report: congenital salivary gland analage tumor presenting with neonatal respiratory distress. Pediatr Pathol Mol Med. 2003; 22: 209-11.
16. Michal M, Sokol L, Mukensnabl P. Salivary gland anlage tumor. A case with widespread necrosis and large cyst formation. Pathology 1996; 28: 128-30.
17. Swayampakula AK, Ischander M, Zuppan CW, Krishnan M, Tong e K, Qureshi S. Newborn with congenital salivary gland anlage tumor presenting with respiratory distress. International Journal of Pediatric Otorhinolaryngology Extra 2015; 10: 42–4.
18. Azma R, Fallahi M, Khoddami M, Shamsian BS, Alavi S. Congenital Pleomorphic Adenoma in a SubmandibularGland of a Newborn- A Case Report. Iran J Otorhinolaryngol. 2016; 28: 153-7.
19. Johns ME. The salivary glands: anatomy and embryology. Otolaryngol Clin North Am. 1977; 10: 261-71.